



Contents lists available at ScienceDirect

International Journal of Surgery

journal homepage: www.theijs.com



Experience with the Wise mammoplasty skin resection pattern in skin-sparing mastectomy and immediate breast reconstruction for large breast volumes ☆, ☆☆☆, ☆☆☆☆

M. Di Candia^b, K.H. Lie^a, P. Forouhi^c, C.M. Malata^{b,c,*}

^a University of Cambridge School of Clinical Medicine, Cambridge, UK

^b Department of Plastic and Reconstructive Surgery, Addenbrooke's Hospital, Box 186, Hills Road, Cambridge CB2 2QQ, UK

^c Cambridge Breast Unit, Addenbrooke's Hospital, Cambridge, UK

ARTICLE INFO

Article history:

Received 15 April 2010

Received in revised form

18 July 2010

Accepted 23 August 2010

Available online xxx

Keywords:

Skin-sparing mastectomy

Wise mammoplasty pattern

Complications

Immediate breast reconstruction

Large breasts

Axillary clearance

ABSTRACT

Introduction: Skin-sparing mastectomy (SSM) and immediate breast reconstruction (IBR) remain technically challenging in very large breasted women, often requiring extensive skin reduction, with a high incidence of post-operative complications. We report our retrospective experience (1999–2007) with SSM and Wise pattern skin reduction in IBR, and examine factors contributing to recipient site post-operative complications. **Results:** 29 reconstructions comprising 16 free TRAM/DIEPs, 5 pedicled TRAMs, and 8 implant-based ones were undertaken in 25 patients aged 32–70 years (median = 48). Their mean BMI was 30.4 kg/m² ($r = 22.3$ –39.3) and 6/25 were current smokers. There were 14 (48%) associated axillary clearances. All breasts had grade 2 or 3 ptosis. The mastectomies weighed 805 g–1972 g (mean = 1326). Sixteen operations (55%) developed complications; 7 minor, 9 requiring further surgical intervention. Of these 16 cases, 13 involved skin complications and 9 involved culture-proven wound infections. All patients achieved satisfactory aesthetic outcomes. At median cancer follow-up of 24 months ($r = 2$ –98), there have been no local recurrences but two deaths from distant metastases. Mastectomy weight was significantly associated with major skin complications requiring surgery (age-adjusted OR per 100 g = 1.6; CI = 1.1–2.3, $p = 0.02$). Performance of axillary clearance at the time of skin-sparing mastectomy was significantly associated with risk of post-operative infection (age-adjusted OR = 5.8; CI = 1.3–26.0, $p = 0.021$). These relationships were maintained after adjusting for patient, surgical and tumour factors.

Conclusion: Wise pattern skin reduction is a useful technique for managing large, ptotic breasts during SSM and IBR. Increasing breast size and the type of cancer surgery are important predictors of post-operative complications.

© 2010 Published by Elsevier Ltd on behalf of Surgical Associates Ltd.

1. Introduction

Immediate breast reconstruction following skin-sparing mastectomy is oncologically safe,^{1–4} and provides significant aesthetic advantages (such as improved colour and texture match as well as less visible scarring) over its alternatives.^{5–9} The

incisional patterns described for skin-sparing mastectomy include the periareolar,^{10,11} elliptical,² Wise,^{12–14} LeJour^{9,15,16} and Regnault-B patterns.¹⁷ Some of these designs have reportedly high incidence of local post-operative complications.^{14,18} For instance the Wise pattern is associated with delayed wound healing and mastectomy skin flap necrosis in as many as 20–30% of cases.^{13,19} This is because of the combination of thin, relatively long and easy devascularized skin flaps with the presence of a T-junction which predisposes to various post-operative wound healing problems (Fig. 1a). Despite these shortcomings, the Wise pattern remains in widespread use for mastectomies of very large and/or severely ptotic breasts allowing acceptable outcomes (Fig. 1b).

It was therefore our aim to better understand the risk factors contributing to these complications so as to be able to comprehensively advise future patients contemplating immediate breast reconstruction facilitated by Wise pattern skin reduction.

☆ 56th Congress of the Italian Society of Plastic and Reconstructive Surgery (SICPRE), Fasano-Brindisi (Italy), September 26–29, 2007.

☆☆ 42nd Congress of the European Society of Surgical Research (ESSR), Warsaw (Poland), May 21–24, 2008.

☆☆☆ British Association of Plastic, Reconstructive and Aesthetic Surgeons (BAPRAS) Summer Scientific Meeting, Liverpool (UK), July 9–11, 2008.

* Corresponding author. Department of Plastic and Reconstructive Surgery, Addenbrooke's Hospital, Box 186, Hills Road, Cambridge, CB2 2QQ, U.K. Tel.: +0044 1223 58667; fax: +0044 1223 257177.

E-mail address: cmalata@hotmail.com (C.M. Malata).

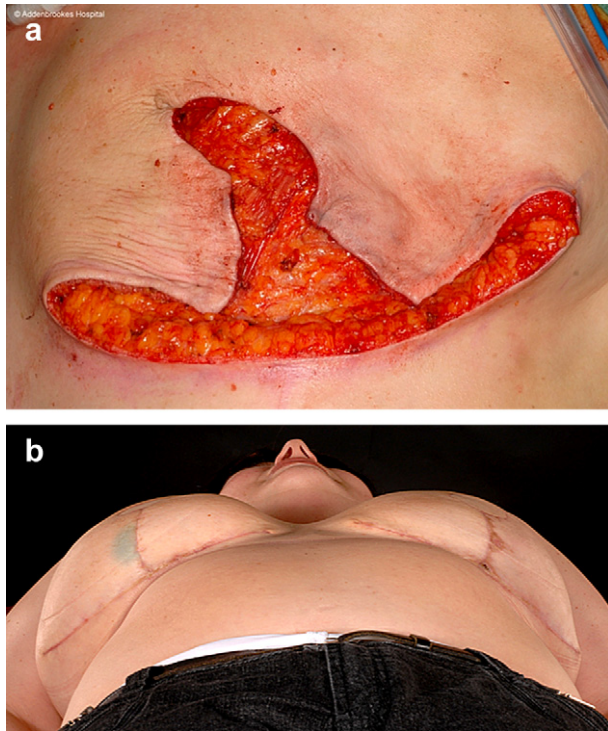


Fig. 1. In (a), note the long and thin lateral and medial skin flaps left behind after Wise pattern mastectomy. They are easy to devascularize and hence prone to post-operative wound healing problems. (b) shows an inferior view of the T-scar left after IBR facilitated by a Wise pattern skin reduction.

2. Patients and methods

A retrospective study of all patients undergoing Wise pattern skin reduction during their skin-sparing mastectomy and immediate breast reconstruction from 1999 to 2007 was undertaken. Patients were identified from the theatre register and surgeons' log-books.

Patients' details with respect to age, BMI, smoking status and co-morbidity were recorded. Indications for surgery including cancer, breast cup-size and ptosis grade were also noted. The surgical details of interest were: mastectomy weight, associated axillary clearance, specific reconstruction type and simultaneous contralateral balancing surgery.

The post-operative outcomes were analysed in terms of specific wound healing problems, infections and "other" complications. The aesthetic results were assessed subjectively by the patient and the surgeon at outpatient follow-up.

3. Results

Wise pattern skin reduction was used in 25 patients aged 32–70 years (median = 48) to facilitate 29 immediate breast reconstructions undertaken following 22 curative and 7 prophylactic mastectomies. The average BMI of the patients was 30.4 kg/m² (range = 22.3–39.3) and six of them were current smokers (24%). All breast operated on had either grade 2 or 3 ptosis. The bra cup-sizes, where recorded, were 4 ≤ D, 4 = DD, 6 ≥ E. The mean weight of the mastectomies was 1326 g (range = 805 g–1972 g).

Of the 22 curative mastectomies undertaken, 14 (64%) had associated axillary node clearance. The reconstructive methods used are summarized in Table 1. 58% of the unilateral reconstructions (11/19) underwent simultaneous contralateral balancing surgery, involving either mastopexy or breast reduction. Another 4 patients had simultaneous contralateral prophylactic mastectomies and immediate breast reconstruction. 66% (19/29) of all surgeries were therefore bilateral. About half (13/25) of the patients had received either neoadjuvant (9/25) or adjuvant (4/25) chemotherapy. Almost a third of all reconstructed 9/29 (31%) breasts went

Table 1
Reconstructive methods used after Wise pattern skin-sparing mastectomy.

Method	Number of reconstructions
DIEP flap	8
Free TRAM flap	8
Pedicle TRAM flap	5
LD flap with implants	7
Implant-only	1

on to receive adjuvant radiotherapy, while 4/29 (14%) breasts had had radiotherapy in the past following breast conserving surgery.

Of the 29 reconstructions only 13 (45%) made totally uncomplicated post-operative recoveries. Seven reconstructions developed minor complications which were managed conservatively (Fig. 2a–c) but 9 cases needed surgical intervention (Fig. 3a–c). Table 2 summarizes the various complications that were encountered. The various skin complications were inter-related and hence difficult to quantify individually – skin necrosis inevitably leads to delayed wound healing and often wound dehiscence. Similarly, T-junction breakdown is closely related to the above problems. There were also 9 cases of culture-proven wound infections.

Multivariate statistical analysis of the outcomes to determine the possible predictors of morbidity revealed that mastectomy weight was significantly associated with major skin complications requiring further surgery (age-adjusted Odds Ratio per 100 g of breast tissue = 1.6 CI: 1.1–2.3, $p = 0.02$). Performance of axillary clearance at the time of skin-sparing mastectomy was significantly associated with risk of post-operative infection (age-adjusted Odds Ratio = 5.8, CI = 1.3–26.0, $p = 0.021$). There was an almost six fold increased risk of post-operative wound infection following performance of an axillary dissection at the time of mastectomy. These relationships were maintained after adjusting for BMI, smoking, medical co-morbidity and tumour size and grade.

After an average follow-up of 33 months (range = 2–98), none of our patients developed local recurrence, although two patients have died of distant metastases.

4. Discussion

Although it was the first aesthetic breast skin reduction technique described for use in skin-sparing mastectomy (SSM) and immediate breast reconstruction¹² (IBR), the Wise incisional pattern is now less favoured over other more conservative options, such as the LeJour pattern,^{9,15,16} because of its high incidence of post-operative complications.^{1–5,13,14,18} Despite this the Wise pattern remains in widespread use because it entails the removal of larger areas of excess skin as compared to alternatives such as the LeJour pattern making it particularly suitable for large breasted patients wishing to have smaller breasts after reconstruction. Also, these other techniques may leave behind large floppy skin envelopes with precarious vascularity, which can be difficult to surgically manage during the reconstruction. Additionally it allows greater access to the breast surgeon for performing the mastectomy and axillary clearance, and to the plastic surgeon for facilitating microvascular anastomoses during free flap breast reconstruction. However, there is very little in the literature on the key considerations to be made when contemplating using the Wise pattern for IBR and how such patients should be counselled preoperatively.

In this present study, the Wise pattern was chosen to facilitate IBR of very large and/or significantly ptotic breasts because achieving satisfactory cosmetic results in these patients frequently requires extensive skin reduction. Besides, it allows far greater control over the final shape of the reconstruction because aesthetically it mimics breast reduction or mastopexy.^{20,21}

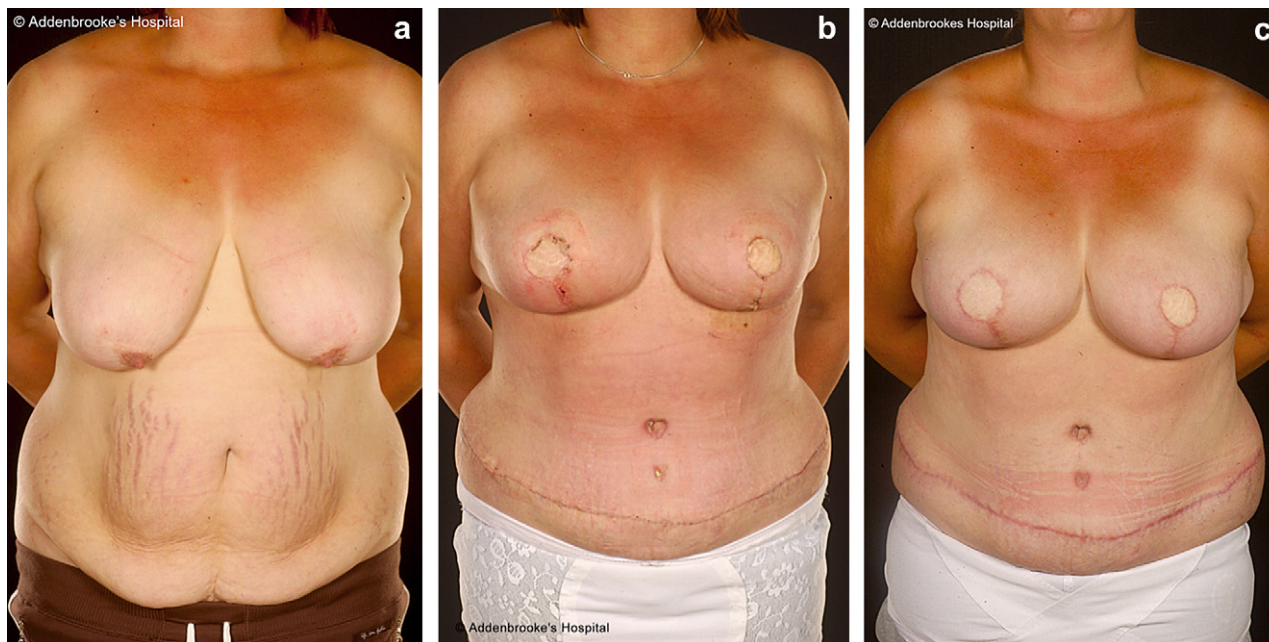


Fig. 2. – A 32 year-old smoker (BMI = 35) with large grade 3 ptotic breasts (a) underwent bilateral prophylactic mastectomies which weighed 1084 g on the right and 1035 g on the left. These were then reconstructed with DIEP flaps. Her post-operative recovery was complicated by minor skin necrosis and T-junction breakdown (b) which was managed conservatively. The reconstructive outcome at 11 months (c) was satisfactory.

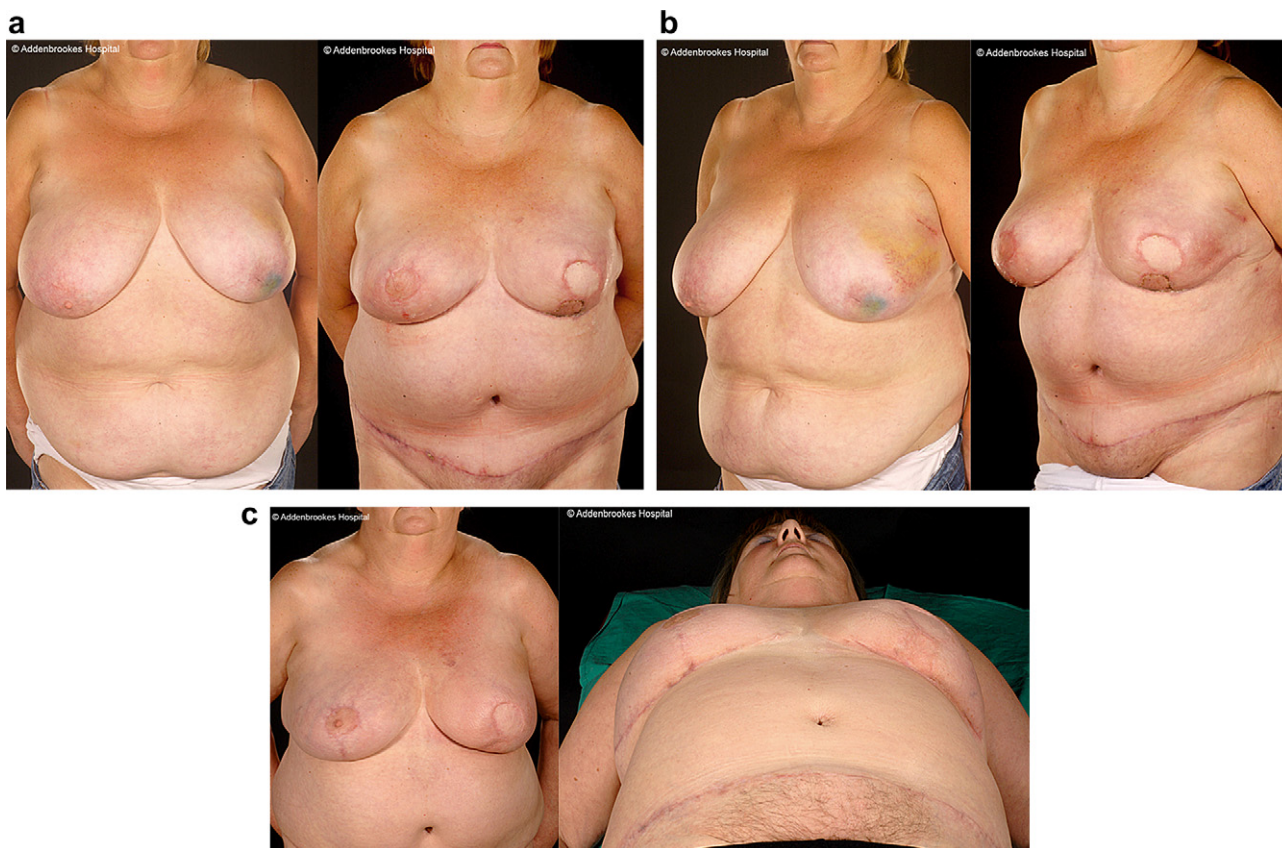


Fig. 3. – This 61 year-old non-smoker (BMI = 35) presented with a 5 cm G3 node-positive invasive ductal carcinoma of the left breast (a–b left side). Following neoadjuvant chemotherapy and a sentinel lymph-node biopsy she underwent Wise pattern skin-sparing mastectomy and axillary clearance. This was immediately reconstructed with a free TRAM flap. The simultaneous contralateral balancing reduction was performed using the Wise pattern as well to maximize symmetry. Postoperatively she developed significant skin necrosis complicated by wound infection and cellulitis which required intravenous antibiotics, debridement and skin grafting (a–b right side). The final appearance 18 months later (c) shows satisfactory outcome with mature skin graft at the T-junction scar. The patient has declined nipple reconstruction.

Table 2
Types of post-operative complications detected.

Type of complication	Frequency
Skin problems	13
-Necrosis	
-T-junction breakdown	
-Delayed wound healing	
-Dehiscence	
Wound infection.	9
Fat necrosis.	2
Haematomas.	1

The current study presents all the patients who underwent both curative and prophylactic “Wise pattern mastectomies” without exclusion, in order to avoid selection bias. A multivariate analysis was used in order to eliminate the effects of concordant variables and reduce the impact of small sub-groups. Although in some centres thicker mastectomy flaps may be used in prophylactic cases, in our unit the breast surgeon (PF) undertakes skin-sparing mastectomies at the same level whether this is for cancer or risk reduction. Although previous breast irradiation predisposes to complications following mastectomy we did not find it to be a significant predictor of complications after immediate breast reconstruction (IBR) using the Wise pattern incisions. This may be due to the small patient numbers.

Multivariate statistical analysis revealed a significant association between mastectomy weight and major skin complications requiring further surgery. For every 100 g increase in mastectomy weight there was a 1.6-fold increased risk of these major complications. Whilst it is well recognized that larger breasts are generally technically more challenging to reconstruct, it is still important

when counselling prospective IBR patients about the high risk (31% in our series) of reoperation for wound-related complications associated with the use of the Wise mammaplasty pattern.

That the significant association between performance of axillary clearance at the time of SSM increased the risk of post-operative infection was a surprising but important finding. In fact, there was a rather large odds ratio of 5.8 for this particular association. A possible explanation for this could be that the impaired lymphatic drainage of the surgical site compromised immune function thus predisposing to infection. It also leads to stasis of tissue fluid, swelling and seroma formation. This finding will need to be confirmed in larger studies.

In “high risk” patients with a number of the important risk factors highlighted above, one would advise caution when proceeding with this type of surgery. Besides the viability of the mastectomy skin flaps should ideally be assessed intra-operatively by techniques such as intravenous fluorescein or indocyanin green.^{22,23} We did not employ this in any of our patients.

Minor complications such as T-junction breakdown or delayed wound healing are often a nuisance because of the need for frequent wound dressing changes. More importantly they can delay the initiation of adjuvant treatments and could thus potentially disadvantage the patient oncologically. This is clinically significant and should form part of the discussion with patient when considering this technique.

Although we have independently confirmed that it is associated with a high incidence of post-operative complications,^{13,19} the Wise skin reduction pattern remains a good option for reconstructing very large or significantly ptotic breasts. It has provided such patients with excellent cosmesis and symmetry (Figs. 2c–4c). From our experience, in spite of the difficulties encountered with the Wise pattern, all our patients eventually achieved successful

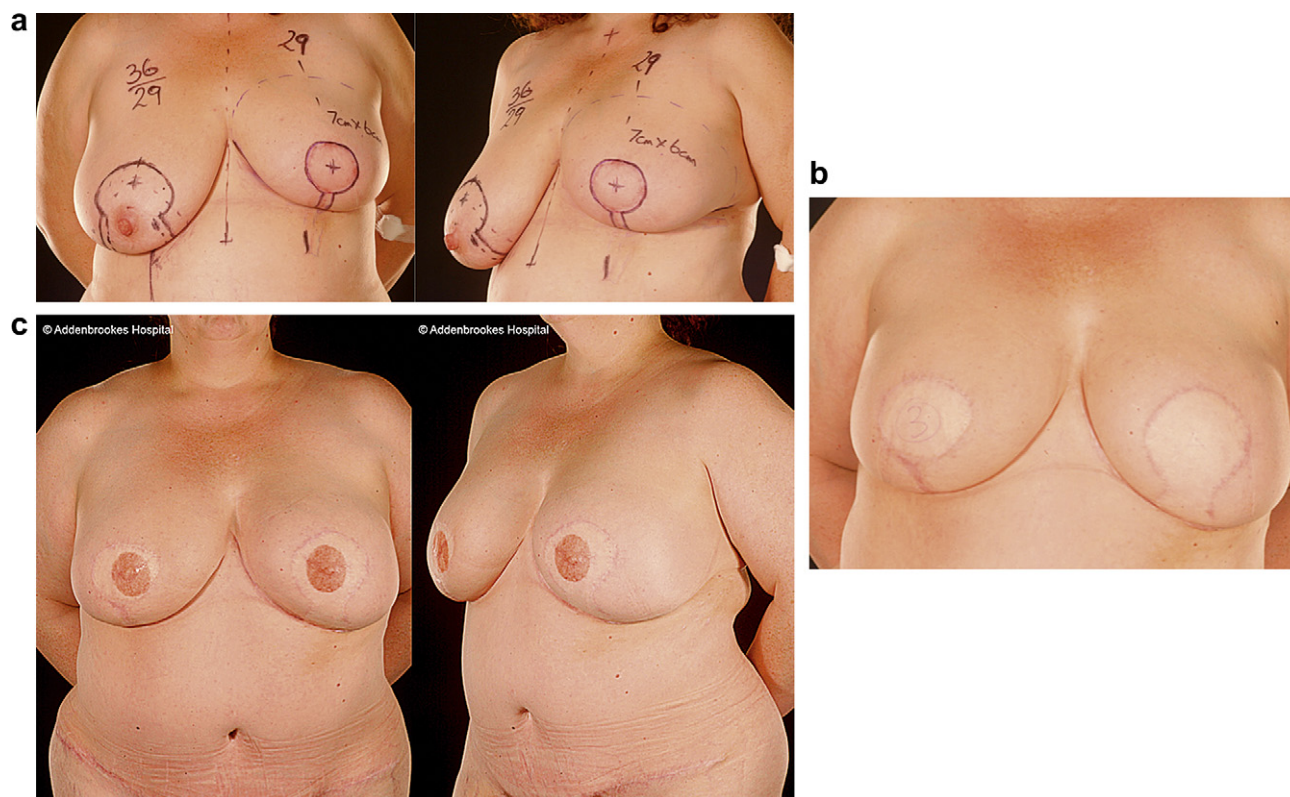


Fig. 4. A 38 year-old lady non-smoker (BMI = 30) underwent bilateral Wise pattern mastectomies and reconstruction with bilateral free DIEP flaps. She previously had a lumpectomy and rearrangement on the left breast. The resections margins were incomplete hence the need further surgery. For the prophylactic mastectomy on the right side the Wise pattern vertical skin excision was designed conservatively (a). Intra-operatively there was excessive tension on the lateral and medial skin flaps on the left side, thereby a vertical skin paddle of the DIEP flap was preserved (b) allowing tensionless closure and problem-free healing. The appearance of the reconstruction five months later (c) was satisfactory.

Table 3

Counselling for large breasted patients requiring Wise pattern skin-sparing mastectomy and IBR.

New findings from our study.

- Risk of reoperation for wound-related complications is 1/3.
- Risks increase significantly with increasing breast size (mastectomy weight).
- Concomitant axillary clearance increases complications 6-fold.
- Probability of uncomplicated recovery is less than 50%.

Previously known risk factors:

- High BMI.
- Heavy smokers (not addressed in this study).
- Previous radiotherapy.

reconstructive outcome and were satisfied with their final cosmetic results. Furthermore, we note the lack of local tumour recurrence, which is in keeping with the established view that skin-sparing mastectomy is oncologically safe.^{2,24}

4.1. Refinements for optimising healing

It is important to minimise surgical complications, especially those requiring surgical intervention or readmission to the hospital. Many of these major complications occurred around the area of the inverted T-junction (at the meeting point of the horizontal and vertical suture lines). It is well known that this is due to the increased tension in this area, as well as the relative thinness of the mastectomy skin flaps²⁵ compared to these made in breast reduction.

To address this we now routinely reduce the tension in the skin closure especially around the T-junctions by designing it conservatively, and lowering the new nipple position compared to reduction mammoplasties (Fig. 4a). Because of the unavoidable thin skin flaps, we recommend a conservative skin resection. In addition, during the surgery, we have a very low threshold for preserving a vertical skin paddle on the donor flap¹⁶ (Fig. 4b) to reduce any perceived or apparent skin tension. In our unit we have also sought to reduce the risks of healing problems associated with the T-junction by eliminating it via the use of the “LeJour pattern mastectomy” technique^{9,16} (where possible). We are currently engaged in a prospective comparison of these two skin reduction techniques in our IBRs. We also now counsel patients needing axillary clearance that they have a 6-fold higher risk of developing wound-related complications (Table 3).

5. Conclusion

Despite the high risk of problems associated with it, the Wise mammoplasty pattern for mastectomy remains a viable option in the aesthetic reconstruction of very large or severely droopy breasts that require extensive skin reduction. However, patients should be fully counselled with regards to the nature and frequency of wound healing problems which may be encountered with this type of immediate breast reconstruction. These risks can be managed and minimised by careful patient selection, as well as using the recommended refinements to the technique.

Conflict of interest

No conflict of interest involved.

Funding

No source of funding.

Ethical approval

None.

References

1. Singletary SE. Skin-sparing mastectomy with immediate breast reconstruction: the M.D. Anderson cancer center experience. *Ann Surg Oncol* 1996;**3**(4):411–6.
2. Carlson GW, Bostwick J, Styblo TM, Moore B, Bried JT, Murray DR, et al. Skin-sparing mastectomy: oncologic and reconstructive considerations. *Ann Surg* 1997;**225**(5):570–8.
3. Constant E. Skin-sparing mastectomy: oncologic and reconstructive considerations. *Plast Reconstr Surg* 1998;**102**(2):590.
4. Malata CM, McIntosh SA, Purushotham AD. Immediate breast reconstruction after mastectomy for cancer. *Br J Surg* 2000;**87**(11):1455–72.
5. Carlson GW, Losken A, Moore B, Thornton J, Elliott M, Bolitho G, et al. Results of immediate breast reconstruction after skin-sparing mastectomy. *Ann Plast Surg* 2001;**46**(3):222–8.
6. Rohrich RJ. Minimally invasive, limited incision breast surgery: Passing fad or emerging trend? *Plast Reconstr Surg* 2002;**110**(5):1315–7.
7. Hultman CS, Meyer AA. Role of skin-sparing mastectomy in breast reconstruction. *Breast Dis* 2002;**16**:15–21.
8. Biggs TM. Limited incision for breast surgery. *Plast Reconstr Surg* 2003;**112**(2):691.
9. Malata CM, Hodgson EL, Chikwe J, Canal ACE, Purushotham AD. Application of the LeJour vertical mammoplasty pattern for skin-sparing mastectomy: a preliminary report. *Ann Plast Surg* 2003;**51**(4):345–50.
10. Grossman PH, Novack BH, Karlan SR, Uyeda RY. An alternative technique for modified radical mastectomy with immediate reconstruction. *Contemp Surg* 1991;**38**:20–4.
11. Knowlton EW, Gorey R, Taekman H. Total immediate breast reconstruction with peg latissimus dorsi flap. *Contemp Surg* 1992;**41**:15–9.
12. Toth BA, Lappert P. Modified skin incisions for mastectomy: the need for plastic surgical input in preoperative planning. *Plast Reconstr Surg* 1991;**87**(6):1048–53.
13. Skoll PJ, Hudson DA. Skin-sparing mastectomy using a modified wise pattern. *Plast Reconstr Surg* 2002;**110**:214.
14. Toth BA, Daane SP, Tenna S. Skin-sparing mastectomy with immediate breast reconstruction: A 10-year, single surgeon review of 105 consecutive patients. *Eur J Plast Surg* 2002;**25**(3):156–9.
15. Young KB, Satovsky N. The vertical pattern breast reconstruction for large or ptotic breasts. *Plast Reconstr Surg* 2005;**115**(7):2052–5.
16. Hunter JE, Malata CM. Refinements of the LeJour vertical mammoplasty skin pattern for skin-sparing mastectomy and immediate breast reconstruction. *J Plast Reconstr Aesthet Surg* 2007;**60**:471–81.
17. Munnoch DA, Preece PE, Stevenson JH. The modified B-mammoplasty incision: an alternative skinconserving technique for mastectomy with immediate breast reconstruction. *Ann R Coll Surg Engl* 1998;**80**(4):257–61.
18. Moshlyedi AK, Vasconez LO. Minimizing complications in breast reconstruction. *Breast Dis* 2002;**16**:141–6.
19. Nava MB, Cortinovic U, Ottolenghi J, Riggio E, Pennati A, Catanuto G, et al. Skin-reducing mastectomy. *Plast Reconstr Surg* 2006;**118**(3):603–10.
20. Hammond DC, Capraro PA, Ozolins EB, Arnold JF. Use of a skin-sparing reduction pattern to create a combination skin-muscle flap pocket in immediate breast reconstruction. *Plast Reconstr Surg* 2002;**110**:206–11.
21. Spear SL, Pelletiere CV, Lockwood M. Immediate breast reconstruction with tissue expanders and AlloDerm. In: Spear SL, Wiley SC, Robb GL, Hammond DC, et al., editors. *Surgery of the breast. USA*: LippincottWilliams and Wilkins; 2006. p. 484–8.
22. Holm C, Mayr M, Höfner E, Becker A, Pfeiffer UJ, Mühlbauer W. Intraoperative evaluation of skin-flap viability using laser-induced fluorescence of indocyanine green. *Br J Plast Surg* 2002 Dec;**55**:635–44.
23. Komorowska-Timek E, Gurtner GC. Intraoperative perfusion mapping with laser-assisted indocyanine green imaging can predict and prevent complications in immediate breast reconstruction. *Plast Reconstr Surg* 2010;**125**(4):1065–73.
24. Simmons RM, Fish SK, Gayle L, La Trenta GS, Swistel A, Christos P, et al. Local and distant recurrence rates in skin-sparing mastectomies compared with non-skin-sparing mastectomies. *Ann Surg Oncol* 1999;**6**:676–81.
25. Martino G, Godard H, Nava M, Benson J, et al. Breast reconstruction with myocutaneous flaps: biomechanical aspects. In: *Oncoplastic and reconstructive surgery of the breast*. London: Taylor & Francis; 2004. p. 141–52.