

Early Experience With an Anatomical Soft Cohesive Silicone Gel Prosthesis in Cosmetic and Reconstructive Breast Implant Surgery

Birgit H. Fruhstorfer, FRCS, Elaine L. B. Hodgson, FRCS (Ed), and Charles M. Malata, FRCS (Plast)

Abstract: Recently, an anatomic breast implant filled with soft cohesive silicone gel was introduced by Mentor Medical Systems onto the European market. This study reports the early experience of a single surgeon with this implant. All patients who received a Contour Profile Gel (CPG) implant from March 2001 to October 2002 were studied. Patient satisfaction with breast shape and consistency was assessed using linear analogue scales with a maximum score of 10. Thirty-five patients received CPG implants for cosmetic (10 patients, 20 breasts) and reconstructive (25 patients, 31 breasts) surgery purposes. Patients were satisfied with their breast shape (mean score: 8.3). Eighty-five percent of the breasts were rated as soft (score ≥ 6). No serious esthetic complications such as implant malposition or significant capsular contracture were observed. Anatomic soft cohesive gel implants provide excellent results in selected cases. They are well accepted by patients and not associated with an increased rate of complications.

Key Words: anatomic implants, soft cohesive silicone gel, breast reconstruction, breast augmentation

(*Ann Plast Surg* 2004;53: 536–542)

Since their introduction by Cronin and Gerow in 1962, silicone gel-filled breast implants have been extensively modified. Most notably, the thickness and coating of the implant shell and the cohesiveness of the contained gel have been changed in an attempt to reduce capsular contracture rates and produce the most natural results. The first-generation

implant had a thick shell and viscous gel, while the second-generation one possessed a much thinner gel and shell.¹ These implants, however, had excessive silicone gel bleed and rupture rates^{2,3}; hence, the development of the third-generation ‘low bleed’ implant containing a barrier-coated shell.¹ Although studies that control all variables except texturing and have adequate numbers are not available, evidence suggests that capsular contracture is less with certain textured implants than with smooth-surfaced implants.^{4–7} Apart from conventional silicone gel with a more liquid character, saline and a more cohesive form of the gel are commonly used as filler materials. The cohesiveness of the gel depends on the extent of molecular cross-linking and the amount of silicone fluid.⁸ The cohesivity grade of the gel can be classified as low (round gel-filled prostheses), medium (prostheses with soft cohesive gel) or high (prostheses with firm cohesive gel).⁹

Presently, 2 basic implant shapes are available, namely, round and anatomic. Anatomic or “teardrop” implants taper from a lower profile superiorly to greater projection in the lower pole, more like the shape of the normal breast. Anatomic breast implants can either be filled with saline or silicone gel. Gel-filled prostheses are in general preferred; they have a more natural feel, are less palpable, and produce less skin wrinkling. In the UK, the first anatomic gel implants to be marketed were the McGhan Style 410 (Inamed Corporation, Santa Barbara, CA) and the Nagor CoGel implant (Nagor Ltd, Isle of Man, British Isles); both of these products contain a firm cohesive gel. In our experience, the main patient complaints about firm cohesive gel implants are the palpable ridging, weight, rigidity, and visibility of the implants, and this is supported by anecdotal reports.¹⁰ Therefore anatomic implants with softer cohesive gels have been introduced by several manufacturers, namely, Anatomic Profile (Polytech Silimed, Duisburg, Germany), Perthese (Hojmed, Stockholm, Sweden), Contour Profile Gel (Mentor Corporation, Santa Barbara, CA) and more recently, McGhan Style 410 Soft Touch, a softer variant of the

Received October 21, 2003 and accepted for publication, after revision, May 15, 2004.

From the Department of Plastic and Reconstructive Surgery and Cambridge Breast Unit, Addenbrooke's Hospital, Cambridge, UK.

The authors have no financial or other relationship to Mentor Medical Systems. Mentor is one of many suppliers of the implants used by the senior author.

Reprints: Mr. C. M. Malata, Department of Plastic and Reconstructive Surgery, Addenbrooke's Hospital, Cambridge CB2 2QQ, UK. E-mail: cmalata@hotmail.com

Copyright © 2004 by Lippincott Williams & Wilkins

ISSN: 0148-7043/04/5306-0536

DOI: 10.1097/01.sap.0000134508.43550.6f

original Style 410. We report our early experience with one of these implants, the Contour Profile Gel implant (Fig. 1).

PATIENTS AND METHODS

All patients who received a Contour Profile Gel implant for either cosmetic or reconstructive breast surgery by the senior author (CMM) from March 2001 to October 2002 were included in this study. All patients were subsequently reviewed in outpatient clinics. Special review clinics were organized in December 2003, where patients were assessed by one of the authors. Following surgery, each patient also received an assessment sheet to record her postoperative satisfaction with the shape and feel of the breast using linear analogue scales each with a maximum score of 10. Patients who underwent implant exchange were additionally asked to evaluate the improvement in their breast shape and feel with the new implants. The same survey was repeated in December 2003.

RESULTS

Thirty-five patients received a Contour Profile Gel (CPG) implant (Fig. 1) over the 20-month study period. The age range was 20 to 69 years (mean: 45 years). Thirty-one patients (89%) attended the special review clinic in December 2003. Mean follow-up time was 23 months (range 1 to 33 months). The implant was used in 10 patients (20 breasts) for cosmetic augmentation and in 25 patients (31 breasts) for postmastectomy breast reconstruction (Table 1).

Most patients undergoing cosmetic augmentation had implants placed in a subpectoral position via inframammary incisions (Fig. 2). The periareolar incision was chosen in 2 patients (Fig. 3). In 1 patient who was excessively concerned about the effect of submuscular implants on exercises, the



FIGURE 1. Photograph of a Mentor Contour Profile Gel breast implant.

TABLE 1. Indications for CPG Implants

| Indication | Breasts |
|--------------------------------------|---------|
| Cosmetic augmentation | 20 |
| Primary surgery | 18 |
| Implant exchange | 2 |
| Breast reconstruction | 13 |
| Immediate* | 9 |
| Delayed | 4 |
| Revision of existing reconstructions | 14 |
| Implant exchange | 12 |
| Augmentation of flap | 2 |
| Contralateral balancing surgery* | 4 |
| Total | 51 |

*Includes 2 patients with existing implants prior to mastectomy and reconstruction.

implants were placed subglandularly. The revisional cosmetic augmentation patient underwent implant exchange because of dissatisfaction with size and medial ridging of the original anatomic firm cohesive gel implants. The CPG implants were placed in the same position as the explants, namely in the subglandular position. The volume of the “cosmetic” implants ranged from 215 mL to 355 mL, with 280 mL being the most frequently used size.

Eighteen patients in the reconstruction group also had a latissimus dorsi myocutaneous flap (Fig. 4). Two patients underwent breast reconstruction with a CPG implant only and 5 patients with an expandable implant (Fig. 5) or a classic expander, which were later replaced by CPG implants. In 13 reconstructions, the CPG implant was inserted at the time of breast reconstruction, which was undertaken either as an immediate or a delayed procedure. The CPG implant was also used to revise existing reconstructions and for contralateral balancing surgery in some cases (Table 1). In the patients undergoing revisional implant surgery, reasons for implant exchange included visible wrinkling (Fig. 5) or ridging, fullness of the upper pole (Fig. 5), discomfort, previous infection, and capsular contracture. The explant was an expandable implant in 9 breasts and a firm cohesive gel implant in 2 breasts. In the single patient who had reconstruction with an expander only, this was replaced with a CPG implant at the second stage of the reconstruction. Concomitant procedures included partial or total capsulectomy, mastopexy, adjustment of the inframammary fold, and scar revision. Two patients had preexisting cosmetic silicone implants in both breasts and underwent immediate postmastectomy breast reconstruction in one breast and simultaneous implant exchange in the contralateral breast. The volume of the implants ranged from 120 mL to 640 mL, with 135 mL, 245 mL, and 315 mL being the most frequently used sizes.

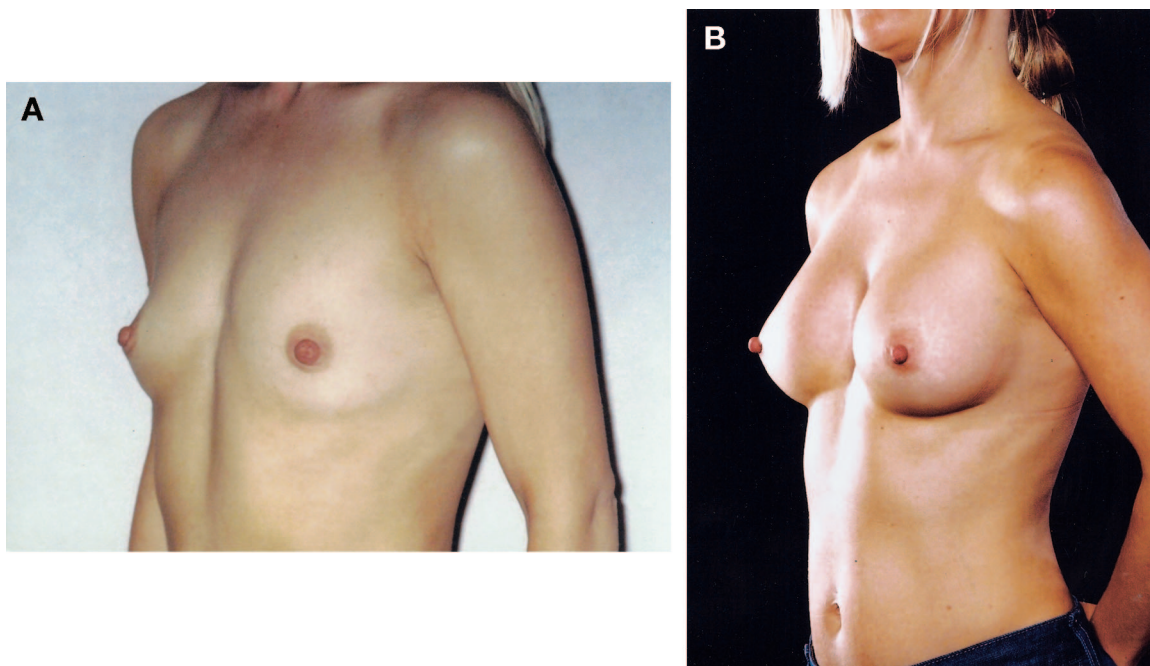


FIGURE 2. Preoperative (A) and postoperative (B) view of a 34-year-old patient who chose an anatomic soft cohesive gel implant for cosmetic breast augmentation. The 215-mL CPG implants were placed subpectorally via inframammary incisions.

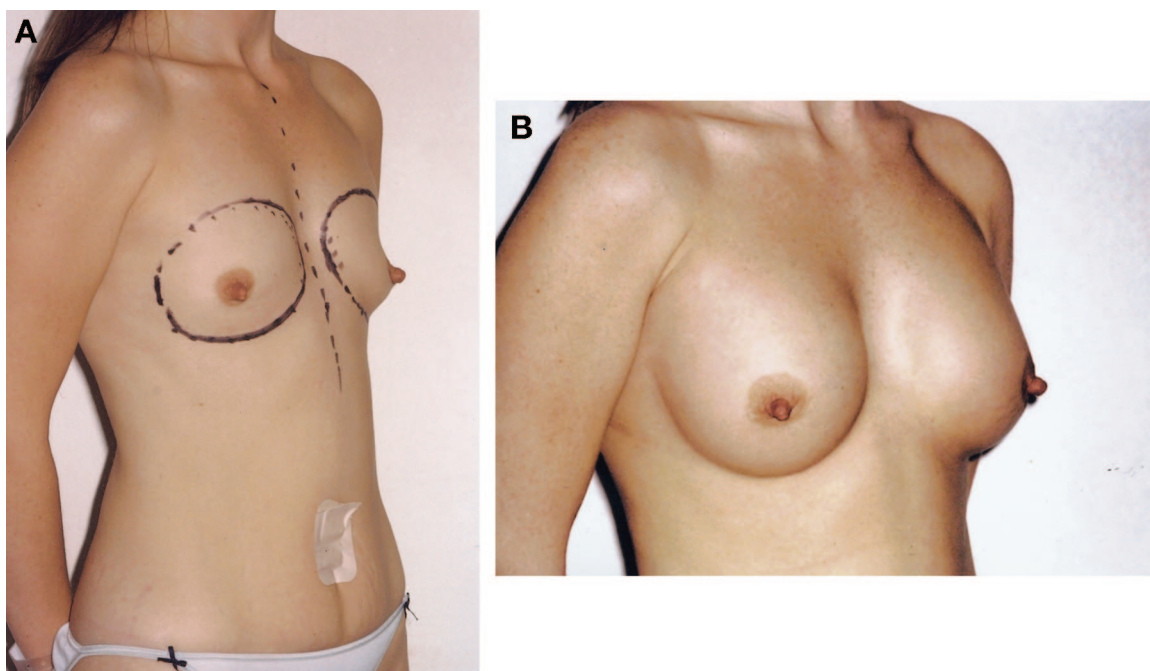


FIGURE 3. Preoperative (A) and postoperative (B) view of a 30-year-old patient, who had periareolar, subpectoral breast augmentation with 280-mL CPG implants.

Postoperative problems related to the implant in the cosmetic augmentation group (Table 2) included postoperative numbness in 4 breasts (2 patients), which recovered fully

in 1 patient. The single revisional cosmetic augmentation patient complained about late postoperative pain in her augmented breasts, which subsided after she was reassured by a

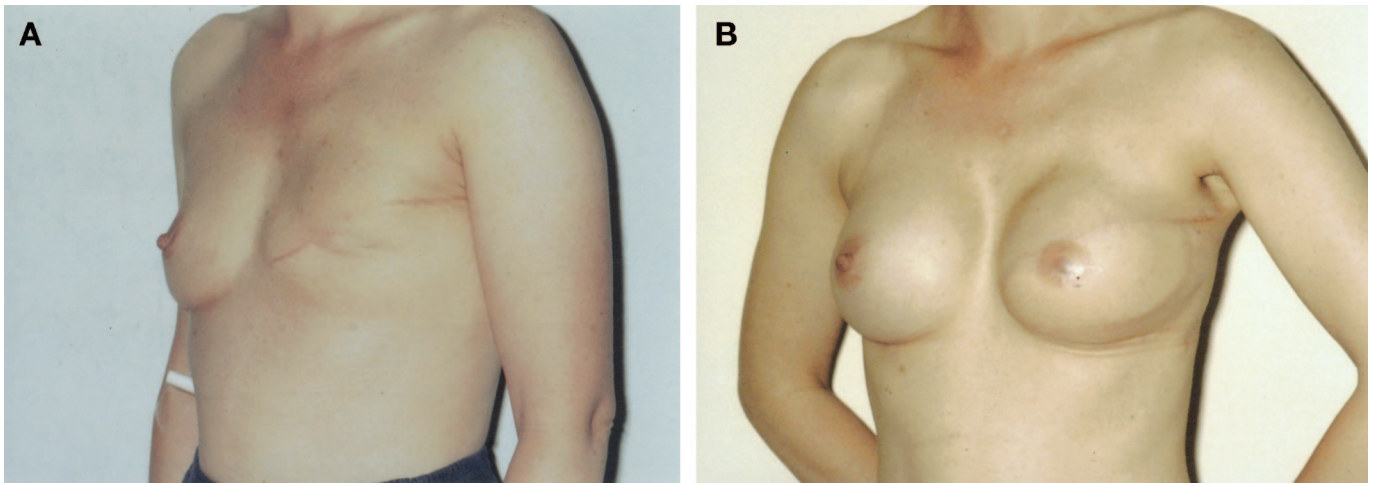


FIGURE 4. Preoperative (A) view of a 38-year-old patient prior to delayed reconstruction with a left latissimus dorsi flap and 120-mL CPG implant. Postoperative appearance (B) following nipple reconstruction and contralateral balancing augmentation with a 135 mL CPG implant.

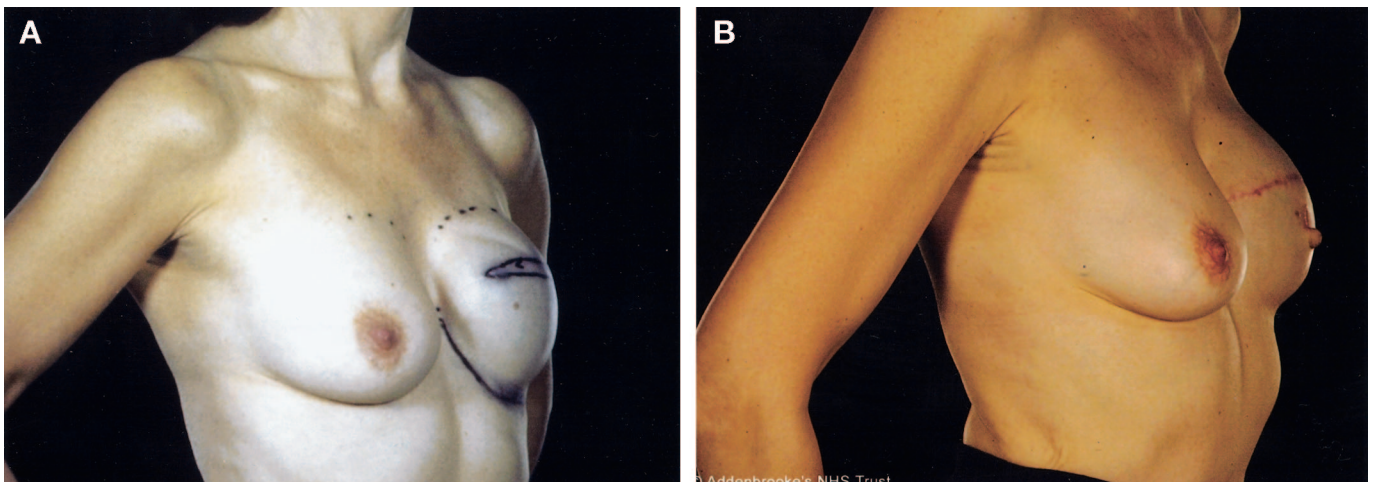


FIGURE 5. Preoperative (A) view of a 54-year-old patient with excessive upper pole fullness and visible wrinkles following delayed breast reconstruction with a round expandable implant. She underwent capsulotomy and replacement with a 315-mL CPG implant (B).

normal MRI breast scan. The esthetic results in this group were excellent (Figs. 2 and 3).

The wound healing was delayed in 2 patients in the reconstruction group (Table 3). One of these was a renal transplant patient on 3 types of immunosuppressants, and the other one had had previous chest wall radiotherapy. A diabetic patient developed cellulitis of the latissimus dorsi flap covering the implant and was successfully treated conservatively. Another reconstruction patient required surgical drainage of a peri-implant breast hematoma following CPG augmentation of a previous totally autologous latissimus dorsi flap. The shape was unsatisfactory in 2 reconstructed breasts, requiring surgery to adjust the low inframammary folds. One

patient who had revisional implant exchange to a CPG implant wished further improvement of her breast shape (Fig. 5). The required height was not available in the CPG range, and therefore it was replaced with a soft cohesive gel implant of a different manufacturer. In 2 patients, the reconstructed breast was too large compared with the normal contralateral side, and they therefore underwent exchange to smaller CPG implants. During the study period, there were no serious esthetic complications such as significant capsular contracture (Baker grade III or IV) or malposition of the implant.

Thirty-two patients (91%) returned the assessment sheets in the first survey, 26 patients (74%) in the second survey. Following surgery, 28 patients were satisfied (score

TABLE 2. Complications in the Cosmetic Augmentation Group

| Complication | Patients |
|-------------------------------|----------|
| Numbness | 2 |
| Pain | 1 |
| Further revision | 0 |
| Malrotation | 0 |
| Capsular contracture (III/IV) | 0 |

TABLE 3. Complications in the Reconstruction Group

| Complication | Patients |
|-------------------------------|----------|
| Hematoma | 1 |
| Delayed healing | 2 |
| Cellulitis of flap | 1 |
| Further revisional surgery | 5 |
| Malrotation | 0 |
| Capsular contracture (III/IV) | 0 |

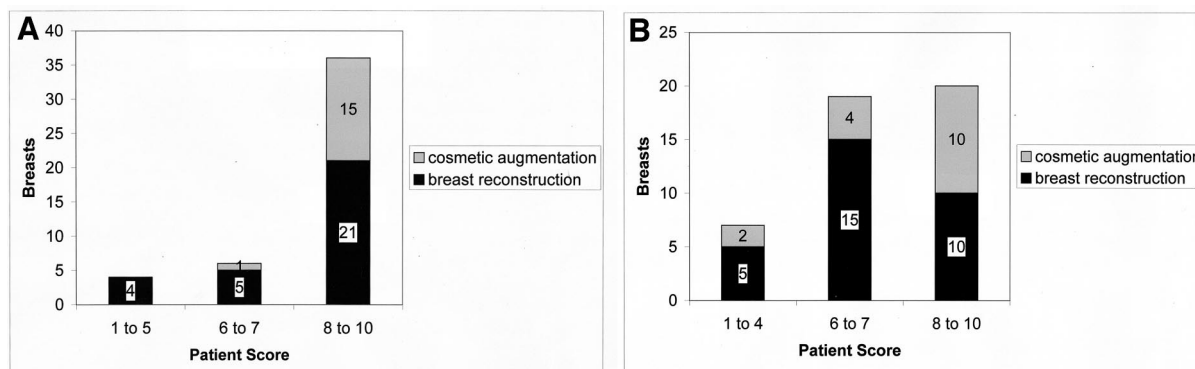
≥ 6) with the shape of their breast (mean score: 8.3; Fig. 6A). In the second survey, similar scores were obtained (mean score: 8.5). In the first survey, 85% percent of the breasts were rated as soft (score ≥ 6 ; Fig. 6B). Results were generally maintained in the second survey, but scores for consistency were improved in 3 breasts (3 points or more); in 4 breasts, the scores dropped by 3 or more. An improvement in shape (score ≥ 6) was reported in 14 out of the 16 breasts in which the CPG implant was replacing another breast prosthesis (mean score: 7.8). In general, the feel of the breast with the new implant was improved (mean score 7.5), and no patient noted it to be worse (Fig. 7). One patient in the revisional reconstruction group was not satisfied with the feel of her breast but still reported a remarkable improvement compared

with the previous implant (score 8). In general, the scores in the cosmetic augmentation group were marginally higher than in the reconstruction group.

DISCUSSION

Today, the plastic surgeon has a wide choice of breast implants in terms of size, shape, shell texture, and filler material when planning cosmetic or reconstructive breast surgery. Choosing the appropriate implant is essential to achieve the best long-term results. Anatomic implants resemble the natural shape of the breast more than round implants and have therefore been generally preferred by many for breast reconstruction.^{1,11} Additionally, they have also been successfully used for cosmetic augmentation.¹²⁻¹⁵ Soft cohesive gel as a filler material has been developed recently to enhance the natural result in terms of breast consistency. In the present series, the soft cohesive gel CPG implant was initially used in patients with preexisting implants to correct problems caused by expandable implants such as palpable wrinkling or those caused by firm cohesive gel such as medial ridging. Because of the good initial experience, it was subsequently also used as the primary implant for both cosmetic augmentation and breast reconstruction. Indications for the CPG implant in cosmetic augmentation included patient request, mild ptosis, and minimal shape to the breast. Both the augmentation and the reconstruction groups were in general satisfied with their final result, despite the need for further revisional surgery in some patients of the reconstruction group.

It has been questioned whether any actual difference exists between anatomic and round implants once they are in situ.^{16,17} Hamas¹⁷ radiographically studied the shape of 21 anatomic and 52 round, maximally filled saline implants with the patients in an upright position. A smaller number was also examined in the recumbent position. Both types of implants assumed a similar teardrop shape with the patients upright. In contrast, in the recumbent position the round implants settled

**FIGURE 6.** Patient satisfaction with postoperative breast shape (A) and consistency (B).

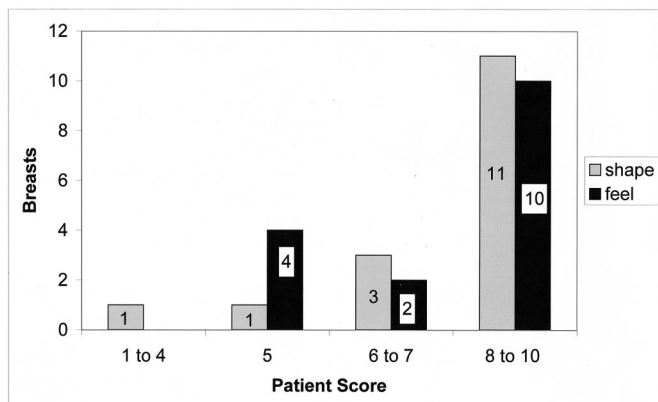


FIGURE 7. Improvement in breast shape and consistency in patients who underwent revisional implant surgery to CPG implants.

back like natural breasts, while the anatomic implants retained their teardrop shape. This unnatural appearance of breasts with anatomic implants in the supine position was also observed earlier by Kisner.¹⁸ Hamas's¹⁷ findings have, however, been disputed by others.¹³ Furthermore, it needs to be considered that the potential of a round implant to assume an anatomic shape in the erect position depends on the filling volume and the periprosthetic space.¹⁹ The results obtained by Hamas with saline implants cannot be reliably extrapolated to implants with more cohesive fillers such as the ones used in the present study.

Implants with soft cohesive silicone gel such as the CPG prosthesis were developed because they combine the desired properties of both gels, the traditional minimally cohesive silicone gel and firm cohesive gel. Firm cohesive silicone gel, unlike traditional silicone gel, is form-stable and, in case of implant rupture, remains confined inside the implant, which is reassuring for patients. Compared with traditional silicone gel, it is, however, considerably firmer. In the present study, with a soft cohesive gel implant most patients assessed their breasts as soft. Furthermore, most patients who received the CPG implant to replace another implant type noticed an improvement in the feel of their new breast. Several of them reported that their breasts had felt hard and unnatural prior to implant exchange. The overall reported improvement in feel, was, however, not as remarkable as expected, especially in reconstruction patients, which shows that even an ideal implant falls short of the consistency of breast tissue and has its limitations. There is, however, a paucity of literature on anatomic, soft cohesive gel implants. To date, only 1 other study has reported on this kind of implant.⁹ Bogetti et al⁹ undertook cosmetic subglandular augmentation using Polytech Silimed code 20675 prostheses in 14 thin patients. Similar to the present study, they reported very satisfactory results. Silicone gel-filled implants are still

not generally available in the United States, largely because of the possible association of silicone breast implants with connective tissue disease. No evidence of such an association was found in a comprehensive meta-analysis²⁰ and this subject has been recently reviewed by the senior author.²¹

One of the concerns with cohesive gel implants in cosmetic augmentation is that access is more difficult than with standard minimally cohesive silicone gel implants, and therefore the incisions have to be made larger. We found no problems in this regard, and we did not alter our standard breast augmentation technique of a 4-cm inferolateral inframammary crease incision. This may be because of the softer cohesive filler material of the CPG implant compared with the firm cohesive gel implant. Intrapocket positioning and adjustment were not problematic and were aided by the placement markers on the front and back of the prosthesis. Surgeons unfamiliar with these implants may, however, choose to make the incision 1 cm longer.¹⁴ Unlike other cohesive gel implants, the CPG implant is at present only available in 1 projection and 1 height for a given volume and is thus best suited to the "average" patient.

None of our patients experienced any significant capsular contracture (Baker grade III or IV) during the short study period. This is in accordance with the findings of Bogetti et al⁹ in a small study of subglandular breast augmentation with soft cohesive silicone gel implants. It has been hypothesized that this may be attributable to the insignificant silicone gel bleed of cohesive gel implants.¹⁴ There were no incidences of implant malposition, which has been previously reported, secondary to in situ rotation of anatomic implants.^{22,23} In Baeke's retrospective analysis of 159 patients with anatomic saline implants, the risk of malposition was at least 14%.²⁴ However, other authors have reported a much lower implant malposition rate.^{14,25} For instance Heden et al¹⁴ implanted 1676 anatomic cohesive gel implants, and postoperative malposition occurred in only 1.1% of cases. Malposition may be more related to errors in implant selection or suboptimal techniques of pocket dissection and pocket dimensions.²⁶

Our early experience shows that anatomic soft cohesive gel implants are well accepted by the patients, without an increased rate of serious esthetic complications as malposition or capsular contracture. They provide natural results in selected cases and can start to be adopted for general use in both cosmetic and reconstructive breast surgery.

ACKNOWLEDGMENTS

The authors would like to thank Mrs. Sue Ramsey, Medical Secretary, for her organizational support.

REFERENCES

1. Young VL, Watson ME. Breast implant research. *Clin Plast Surg.* 2001;28:451-483.

2. Malata CM, Varma S, Scott M, et al. Silicone breast implant rupture: common/serious complication? *Med Prog Tech*. 1994;20:251–260.
3. Collis N, Sharpe DT. Silicone gel-filled breast implant integrity: a retrospective review of 478 consecutively explanted implants. *Plast Reconstr Surg*. 2000;105:1979–1985.
4. Collis N, Coleman D, Foo ITH, et al. Ten-year review of a prospective randomised controlled trial of textured versus smooth subglandular silicone gel breast implants. *Plast Reconstr Surg*. 2000;106:786–791.
5. Hakelius L, Ohlsen L. Tendency to capsular contracture around smooth and textured gel-filled silicone mammary implants: a 5-year follow-up. *Plast Reconstr Surg*. 1997;100:1566–1569.
6. Malata CM, Feldberg L, Coleman DJ, et al. Textured or smooth implants for breast augmentation? three year follow-up of a prospective randomised controlled trial. *Br J Plast Surg*. 1997;50:99–105.
7. Hakelius L, Ohlsen L. A clinical comparison of the tendency to capsular contracture between smooth and textured gel-filled silicone mammary implants. *Plast Reconstr Surg*. 1992;90:247–254.
8. LeVier RR, Harrison MC, Cook RR, et al. What is silicone? *Plast Reconstr Surg*. 1993;92:163–167.
9. Bogetti P, Boltri M, Balocco P, et al. Augmentation mammoplasty with a new cohesive gel prosthesis. *Aesth Plast Surg*. 2000;24:440–444.
10. Hodgkinson DJ. Buckled upper pole breast style 410 implant presenting as a manifestation of capsular contraction. *Aesth Plast Surg*. 1999;23:279–281.
11. Hidalgo DA. Breast augmentation: choosing the optimal incision, implant and pocket plane. *Plast Reconstr Surg*. 2000;105:2202–2216.
12. Heitmann C, Schreckenberger C, Olbrisch RR. A silicone implant filled with cohesive gel: advantages and disadvantages. *Eur J Plast Surg*. 1998;21:329–332.
13. Hobar PC, Gutowski K. Experience with anatomic breast implants. *Clin Plast Surg*. 2001;28:553–559.
14. Heden P, Jernbeck J, Hober M. Breast augmentation with anatomical cohesive gel implants. *Clin Plast Surg*. 2001;28:531–552.
15. Niechajev I. Mammary augmentation by cohesive silicone gel implants with anatomic shape: technical considerations. *Aesth Plast Surg*. 2001;25:397–403.
16. Hamas RS. The postoperative shape of round and teardrop saline-filled breast implants. *Aesthetic Surg J*. 1999;19:369–374.
17. Hamas RS. The comparative dimensions of round and anatomical saline-filled breast implants. *Aesthetic Surg J*. 2000;20:281–290.
18. Kisner WH. Round versus tear-drop breast prostheses: their superiority when supine. *Br J Plast Surg*. 1977;30:284–286.
19. Spear SL, Mardini S. Alternative filler materials and new implant designs. *Clin Plast Surg*. 2001;28:435–443.
20. Janowsky EC, Kupper LL, Hulka BS. Meta-analyses of the relation between silicone breast implants and the risk of connective-tissue disease. *N Engl J Med*. 2000;342:781–790.
21. Spear SL, Malata CM. Silicone autoimmune disease: a systematic approach to patient management. In: Singletary SE, Robb G, eds. *Advanced Therapy of Breast Disease*. Hamilton: BC Decker Inc; 2000: 221–239.
22. Baeke JL. Warning about anatomical breast implants. *Plast Reconstr Surg*. 2000;106:740.
23. Baeke JL. Reply: teardrop implants: enough to make a grown man cry. *Plast Reconstr Surg*. 2001;107:1914–1917.
24. Baeke JL. Breast deformity caused by anatomical or teardrop implant rotation. *Plast Reconstr Surg*. 2002;109:2555–2567.
25. Tebbetts JB. Patient acceptance of adequately filled breast implants using the tilt test. *Plast Reconstr Surg*. 2000;106:139–147.
26. Tebbetts JB. Warning about a warning about anatomical implants. *Plast Reconstr Surg*. 2001;107:1912–1914.