



ELSEVIER



## CASE REPORT

# Cowden syndrome and reconstructive breast surgery: Case reports and review of the literature

E. Ali <sup>a</sup>, P.G. Athanasopoulos <sup>b</sup>, P. Forouhi <sup>a</sup>, C.M. Malata <sup>a,b,\*</sup>

<sup>a</sup> Cambridge Breast Unit, Addenbrooke's University Hospital, Cambridge, UK

<sup>b</sup> Department of Plastic & Reconstructive Surgery, Addenbrooke's University Hospital, Cambridge, UK

Received 26 August 2009; accepted 30 April 2010

## KEYWORDS

Cowden syndrome;  
Phosphatase and tensin  
homologue on  
chromosome ten  
(*PTEN*);  
Prophylactic  
mastectomy;  
Immediate breast  
reconstruction;  
Expandable implants

**Summary** Cowden syndrome (CS) is a rare, autosomal dominant inherited disorder associated with multiple benign and malignant neoplasms, including breast cancer. Prophylactic resection of susceptible organs remains controversial.

We briefly describe the syndrome and review management of the risk of CS-associated malignancies. Three cases of bilateral risk-reducing mastectomy and immediate breast reconstruction are described.

© 2010 British Association of Plastic, Reconstructive and Aesthetic Surgeons. Published by Elsevier Ltd. All rights reserved.

The phosphatase and tensin (*PTEN*) homologue on chromosome ten is a tumour suppressor gene involved in the PI3K/Akt/mTOR pathway which regulates several critical cellular functions including cell proliferation, apoptosis and migration.<sup>1</sup> A germline mutation in the *PTEN* gene results in Cowden syndrome (CS) (Table 1a). CS has a Caucasian and female predominance<sup>2</sup> and a prevalence of 1/200,000

population.<sup>3</sup> Many cases are considered unrecognised due to the variable phenotype of the disease<sup>4</sup> so this figure is likely to be an underestimate.

CS is associated with an increased risk of developing neoplasia of tissues derived from all three embryonic germ cell layers, especially of the breast, thyroid and endometrium.<sup>2</sup> Management options range from observation and screening, to surgery for diagnosed cancer. The lifetime risk associated with the development of thyroid cancer, mostly follicular, is up to 10% in both genders compared to <1% in the general population. Endometrial cancer, mainly adenocarcinoma, has an estimated lifetime risk of up to 10% compared with <2.5% in the general population. The lifetime risk of developing breast cancer for a woman

\* Corresponding author at: Department of Plastic and Reconstructive Surgery, Addenbrooke's Hospital, Cambridge University Hospitals NHS Foundation Trust, Cambridge, CB2 2QQ, United Kingdom. Tel.: +44 1223 586672; fax: +44 1223 257177.

E-mail address: [cmalata@hotmail.com](mailto:cmalata@hotmail.com) (C.M. Malata).

1748-6815/\$ - see front matter © 2010 British Association of Plastic, Reconstructive and Aesthetic Surgeons. Published by Elsevier Ltd. All rights reserved.

doi:10.1016/j.bjps.2010.04.047

**Table 1a** The pathognomonic, major and minor features of Cowden Syndrome according to US National Comprehensive Cancer Network (NCCN) Genetics/High Risk Panel operational diagnostic criteria for 2008.

| Pathognomonic features   | Major features  | Minor features  |
|--|---|---|
| <ul style="list-style-type: none"> <li>• Lhermitte-Duclos disease</li> <li>• Mucocutaneous neoplasms (trichilemmomas, acral keratoses, verucoid or papillomatous papules)</li> </ul> | <ul style="list-style-type: none"> <li>• Breast cancer</li> <li>• Follicular or papillary thyroid cancer</li> <li>• Macrocephaly</li> <li>• Endometrial cancer</li> </ul> | <ul style="list-style-type: none"> <li>• Structural thyroid lesions e.g. adenomas or multinodular goitres</li> <li>• Mental retardation with IQ <math>\leq</math> 75</li> <li>• Gastro-intestinal tract hamartomas</li> <li>• Fibrocystic breast disease</li> <li>• Lipomas</li> <li>• Fibromas</li> <li>• Genitourinary tumours or structural malformations</li> <li>• Uterine fibroids</li> </ul> |

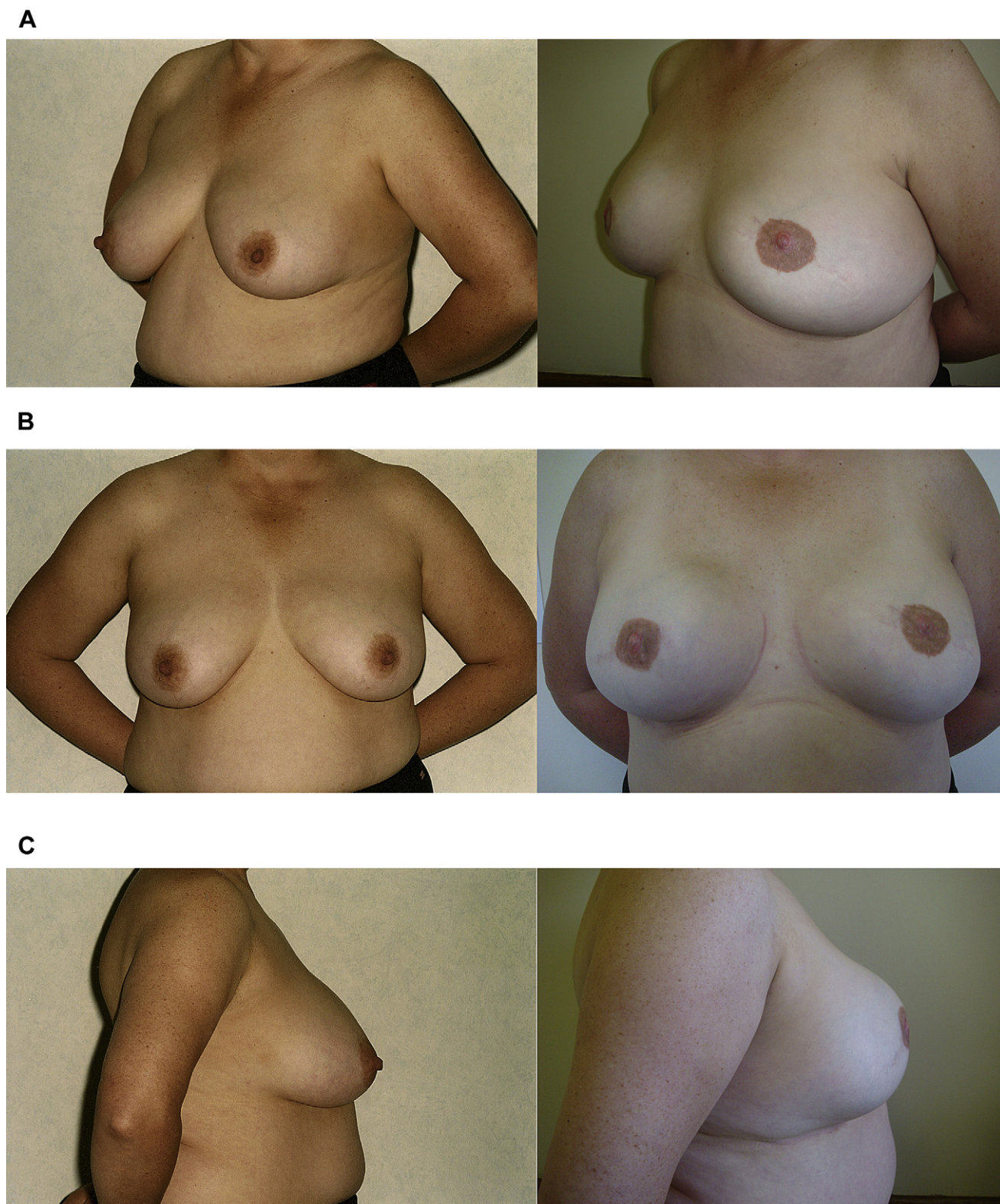
**Table 1b** Summary of the underlying breast disease and the breast reconstruction performed in each of the three cases.

| Case number | Patient age, years | Site of lesion and result(s) of core biopsy  | Breast cup size | Breast surgery performed                                   | Breast reconstruction surgery performed  |
|-------------|--------------------|--|-----------------|--|--|
| 1           | 43                 | No breast lesions were identified  | 38C             | Bilateral skin sparing mastectomy only removing the nipple | Immediate expander reconstruction: Natrelle (formerly McGhan), Style 150 short height expandable implants, Inamed Aesthetic Ltd., Co. Wicklow, Ireland |
| 2           | 25                 | Right sided phyllodes tumour with associated intra duct lobular neoplasia<br>Left sided atypical hyperplasia (Non-malignant lesions associated with an increased risk of developing breast cancer) | 32B             | Bilateral skin sparing mastectomy only removing the nipple | Immediate expander reconstruction: Expander as above   |
| 3           | 47                 | No breast lesions were identified  | 36DD            | Bilateral skin sparing mastectomy only removing the nipple | DIEP and SIEA flaps: Deep inferior epigastric perforator<br>Superficial inferior epigastric artery   |

**Table 1c** Summary of the characteristic features of Cowden Syndrome demonstrated in each of the three cases.

| Case | Macrocephaly | GIT disease                          | Thyroid disease  | Genitourinary disease                      | Other lesions   |
|------|--------------|--------------------------------------|--|--|---|
| 1    | Present      | Gastric, duodenal and colonic polyps | Previous thyroidectomy for benign nodular goitre                             | Previous risk-reducing hysterectomy        | - Hamartomatous tongue nodules<br>- Previous malignant melanoma |
| 2    | Present      | Not present                          | Previous thyroidectomy for a papillary tumour of unknown malignant potential | Normal vaginal US/S and hysteroscopy       | - Hamartomatous tongue nodules                                  |
| 3    | Present      | Not present                          | Previous thyroidectomy for follicular carcinoma                              | Previous hysterectomy for uterine fibroids | Not present   |

US/S, ultra sound scan.



**Figure 1** Pre- and post-operative photographs of two patients who underwent bilateral risk-reducing mastectomy and immediate reconstruction with either implants (style 150 permanent expanders), (a) Left oblique view, (b) anterior-posterior view, (c) right lateral view, or autologous abdominal tissue, (d) right oblique view, (e) anterior-posterior view, (f) left lateral view.

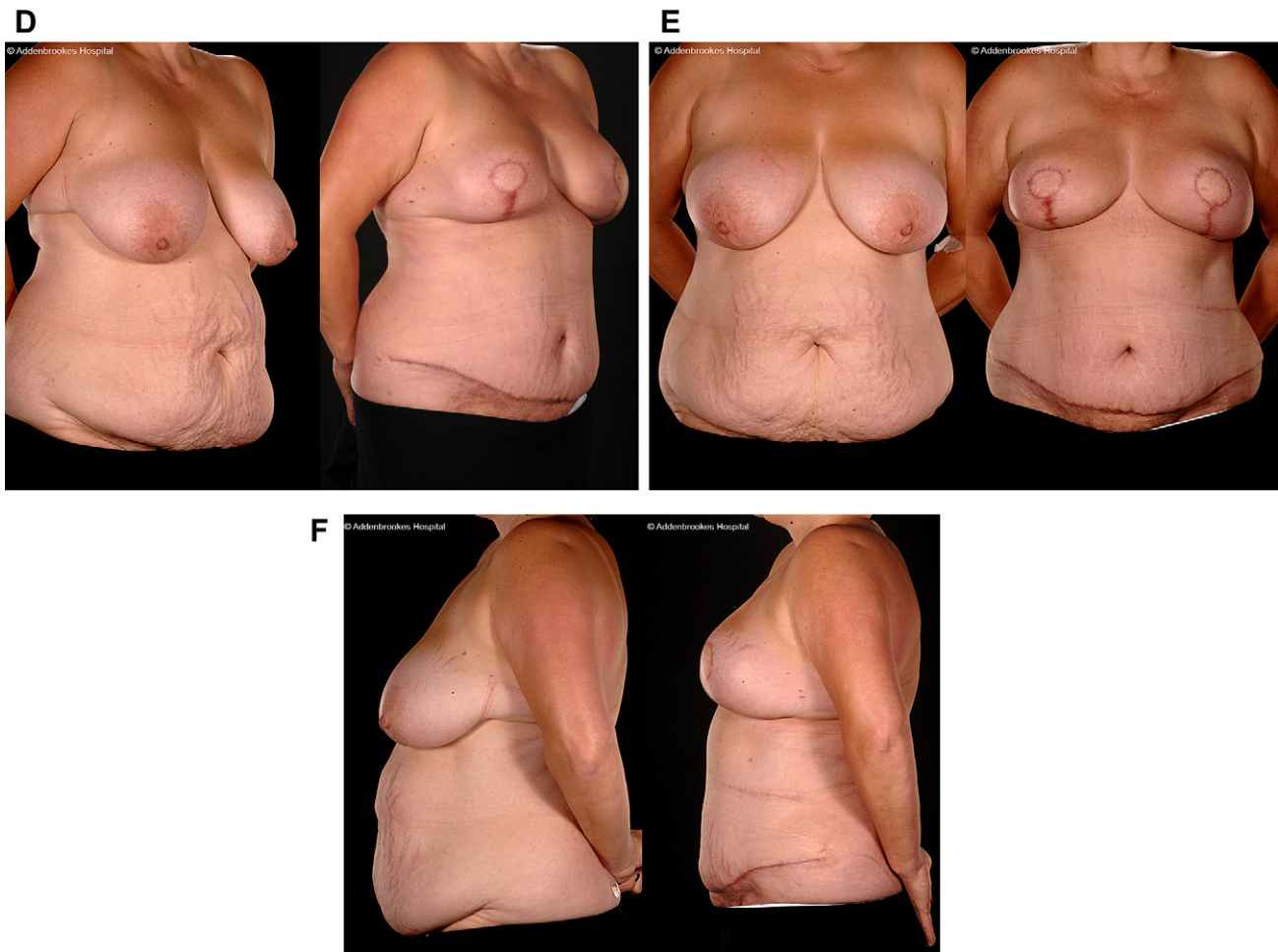


Figure 1 (continued).

diagnosed with CS is 50%, roughly five times that for the general population.<sup>5</sup> The average age for this diagnosis is 36–46 years<sup>6</sup> and the predominant histology is invasive ductal adenocarcinoma.<sup>7</sup>

Bilateral mastectomy is increasingly performed for the management of genetic susceptibility to breast cancer<sup>8</sup> but there is insufficient literature regarding this type of surgery for CS patients. We describe three patients with CS undergoing bilateral mastectomy with immediate breast reconstruction.

### Case reports

Three patients, meeting CS clinical criteria (Table 1a) and having the *PTEN* mutation genetically confirmed, presented to the Cambridge Breast Unit and were referred to the Plastic Surgery Department for consultation regarding breast reconstruction. For details of the patients' underlying breast disease and the reconstructive procedure performed see Table 1b. One of the patients had previously been adequately treated for a phyllodes tumour and 7 months later she underwent risk-reducing mastectomy for prophylaxis of breast cancer. The characteristics of CS demonstrated in each patient are summarised in Table 1c.

### Discussion

We would like to share our experience of the disease and highlight plastic surgical aspects of this condition so as to guide other plastic surgeons with respect to the reconstructive treatment options available. In our cases, we performed bilateral risk-reducing mastectomies with immediate reconstruction because of the patients' young age (Table 1b) and their future risk of developing breast cancer.

Two of our patients underwent implant-based reconstruction. In our opinion, prosthetic reconstruction is the first choice for bilateral procedures because it is a relatively simple technique which easily achieves symmetry as there is no natural breast to match (Figure 1a–c). Although expanders/implants are best suited for small to medium sized breasts historically,<sup>9,10</sup> the newer expandable implants can be used to reconstruct larger breasts<sup>11,12</sup> and were used in two of the three cases presented here. We prefer permanent expandable implants for reconstructions in patients undergoing prophylactic mastectomy as the likelihood of needing radiotherapy is extremely small and hence the risk of significant radiation-induced capsular contracture (requiring operative intervention) is minimal.<sup>13,14</sup> A further consideration in implant-based reconstruction is the

possibility of undertaking other prophylactic surgery on the uterus or thyroid at the same time.<sup>15</sup> Ideally, when implants are used, no other operation should be performed concomitantly due to the potential for causing implant infection by haematogenous spread or cross contamination.

Our third patient underwent bilateral autologous tissue reconstruction. Abdominal tissue is preferable for this when adequate abdominal volume is available as excellent symmetry and cosmetic results can be attained with all breast shapes and sizes (Figure 1d–f). The technique has the added advantage of not requiring intraoperative position changes. Bilateral latissimus dorsi (LD) flaps can be employed but have significant long-term morbidity.<sup>16</sup> Bilateral gluteal artery perforator (GAP) flaps are more complex and either have to be staged or need complicated intraoperative arrangements. For free tissue transfers, we recommend internal mammary recipient vessel use for microvascular anastomoses.

CS is a rare but important inherited pre-disposing factor for breast cancer. Bilateral prophylactic mastectomy and immediate reconstruction substantially reduce the risk of breast cancer while excellent aesthetic results can be obtained using implant-based or autologous reconstructive techniques.

## Acknowledgements

The authors would like to thank Dr. Makam Kishore, Cambridge Breast Unit Fellow, and Dr. Serena Nik-Zainal, Specialist Registrar in Medical Genetics, both in Addenbrooke's Hospital, for providing patients' data and reviewing the manuscript.

## Conflict of interest statement

None.

## Funding source

None.

## References

- Morgensztern D, McLeod HL. PI3K/Akt/mTOR pathway as a target for cancer therapy. *Anticancer Drugs* 2005;16:797–803 [Review].
- Uppal S, Mistry D, Coatesworth AP. Cowden disease: a review. *Int J Clin Pract* 2007;61:645–52.
- Nelen MR, Kremer H, Konings IB, et al. Novel *PTEN* mutations in patients with Cowden disease: absence of clear genotype-phenotype correlations. *Eur J Hum Genet* 1999;7:267–73.
- Eng C. *PTEN*: one gene, many syndromes. *Hum Mutat* 2003;22:183–98.
- Pilarski R. Cowden syndrome: a critical review of the clinical literature. *J Genet Couns* 2009;18:13–27.
- Nusbaum R, Vogel KJ, Ready K. Susceptibility to breast cancer: hereditary syndromes and low penetrance genes. *Breast Dis* 2006;27:21–50.
- Schrager CA, Schneider D, Gruener AC, et al. Clinical and pathological features of breast disease in Cowden's syndrome: an underrecognized syndrome with an increased risk of breast cancer. *Hum Pathol* 1998;29:47–53.
- Batista LI, Lu KH, Beahm EK, et al. Coordinated prophylactic surgical management for women with hereditary breast-ovarian cancer syndrome. *BMC Cancer* 2008;8:101.
- Hodgson EL, Malata CM. Implant-based breast reconstruction following mastectomy. *Breast Dis* 2002;16:47–63.
- Spear SL, Spittler CJ. Breast reconstruction with implants and expanders. *Plast Reconstr Surg* 2001;107:177–87. quiz 188.
- Hsieh F, Shah A, Malata CM. Experience with the Mentor Contour Profile Becker-35 expandable implants in reconstructive breast surgery. *J Plast Reconstr Aesthet Surg*; 2009 Jun 27.
- Cicchetti S, Leone MS, Franchelli S, et al. One-stage breast reconstruction using McGhan Style 150 biodimensional expanders: a review of 107 implants with six years experience. *J Plast Reconstr Aesthet Surg* 2006;59:1037–42.
- Whitfield GA, Horan G, Irwin MS, et al. Incidence of severe capsular contracture following implant-based immediate breast reconstruction with or without postoperative chest wall radiotherapy using 40 Gray in 15 fractions. *Radiother Oncol* 2009;90:141–7.
- Behranwala KA, Dua RS, Ross GM, et al. The influence of radiotherapy on capsule formation and aesthetic outcome after immediate breast reconstruction using biodimensional anatomical expander implants. *J Plast Reconstr Aesthet Surg* 2006;59:1043–51.
- Spear SL, Pennanen M, Barter J, et al. Prophylactic mastectomy, oophorectomy, hysterectomy, and immediate transverse rectus abdominis muscle flap breast reconstruction in a BRCA-2 positive patient. *Plast Reconstr Surg* 1999;103:548–53. discussion 554–555.
- Patani N, Devalia H, Anderson A, et al. Oncological safety and patient satisfaction with skin-sparing mastectomy and immediate breast reconstruction. *Surg Oncol* 2008;17:97–105 [Epub 2008 Feb 21].