

# 51 The principles of breast reconstructive surgery

*Animesh J. K. Patel, Rosanna C. Ching, John R. Benson,  
and Charles M. Malata*

## INTRODUCTION

Increasing numbers of women are diagnosed with breast cancer each year, with estimates of the lifetime risk in western society being 1 in 8 (1). As screening regimes have the potential to pick up cancers earlier, there has been an inevitable increase in the number of patients undergoing surgery for early-stage breast cancers.

Surgical management of invasive and in situ disease can range from wide local excision to total mastectomy. With the emergence of oncoplastic techniques, more patients now have the choice of cancer excision while preserving the breast shape and thus avoiding mastectomy. However, many patients with early breast cancer undergo mastectomy either because of an unfavorable location of the tumor (proximity to the nipple) and its aggressiveness or because the patient prefers this option to breast conservation (perhaps because of a perceived minimization of risk of future disease in the same breast).

Similarly, patients at high risk of breast cancer (e.g., those with a genetic predisposition such as BRCA tumor suppressor gene mutation carriers, those with affected first-degree relatives, and those who have had previous contralateral breast cancer) may choose to have mastectomy as a risk-reducing procedure. These issues relating to future risk have resulted in a rise in the number of patients undergoing mastectomy. Although not all mastectomy patients wish to have a breast reconstruction, a significant number will request this as an option (2) and a variety of techniques are available in the reconstructive surgeon's armamentarium to achieve that aim. For those patients considering risk-reducing mastectomy, the decision to have a mastectomy is perhaps influenced by the availability of reliable and realistic techniques for immediate reconstruction at the same time as mastectomy. Breast reconstruction can free a woman from having to wear an external breast prosthesis, and can go some way to re-establishing self-confidence in her own body image.

The goal of the reconstructive surgeon following breast cancer extirpative surgery can vary from simple wound coverage to the complexities of creating a breast mound that has an esthetically pleasing surface, shape, and volume. In the case of unilateral surgery, the ultimate aim is to achieve symmetry with the contralateral breast. The female breast has unique physical and psychological functions, which collectively contribute to femininity. Reconstructive techniques available today cannot reconstitute the physiological function of the mammary gland. However, the restoration of body image that is lost after mastectomy is surgically achievable and goes a long way in helping restore a woman's self-esteem after having to face the consequences of losing a breast and what it symbolizes.

Although in the planning and execution of breast reconstruction, the reconstructive surgeon must work closely with the breast oncological surgeon, the patient's wishes and expectations are paramount. At the same time, it is important that women understand the limitations of current techniques and the appropriateness of particular procedures in their individual case.

Reconstructive techniques used in breast surgery following mastectomy can be broadly divided into those that use alloplastic materials (i.e., breast implants) and those that use autologous techniques (i.e., the patient's own tissues). There are also techniques that combine these two basic approaches.

Breast implants or prostheses are either saline-filled or silicone-filled medical devices that are available in a variety of shapes and sizes to suit an individual patient but are all designed to augment breast size. The prosthesis requires adequate soft tissue coverage and therefore a pocket for the implant to be placed in must be developed. Often the pocket is expanded to size using a temporary expander or inflatable implant, which is then subsequently exchanged for a fixed-volume implant. In addition to temporary expanders and simple/fixed-volume implants, a further type of prosthesis is also available, which combines the features of a fixed-volume implant and those of an expander. This is called an "expandable implant" or a "permanent expander" (3) and is a popular choice in contemporary breast reconstruction.

Autologous techniques include the use of pedicled and free flaps. A flap is defined as a block of tissue that is "moved" or transferred from one part of the body (donor site) to another (recipient site). A pedicled flap survives by keeping its blood supply intact during flap movement. In free flaps (also known as free tissue transfers), the flap's vascular pedicle, containing its blood supply, is surgically divided at the donor site and then reanastomosed to blood vessels at the recipient site using microsurgical techniques. The main advantage of autologous flaps is that they more closely resemble native breast tissue in their feel and consistency. They also reduce or eliminate the need for prostheses, which being foreign materials carry their own risks. A pertinent consideration in breast reconstruction is that they withstand the effects of radiotherapy better than implant-based or implant-only techniques. Commonly used pedicled flaps in breast reconstruction include the latissimus dorsi (LD) myocutaneous flap and the pedicled transverse rectus abdominis myocutaneous (TRAM) flap. As will be discussed below, often the LD flap alone has insufficient volume to create the breast mound, and an implant or expander is often necessary to provide supplementary volume. Although still used by some surgeons, the pedicled TRAM has largely fallen out of favor and

been superseded by free tissue transfer techniques, most commonly using cognate abdominal tissue (i.e., the free TRAM flap) and its modifications. Other free flaps that have been used successfully for breast reconstruction include buttock flaps using the superior and inferior gluteal arteries and flaps using tissue harvested from the thigh. Each potential donor site has its merits and the choice of which to use must be made on an individual patient basis taking account of tissue availability and the requirements for reconstruction, in terms of size and volume.

### HISTORY OF BREAST RECONSTRUCTION

The Austrian-German surgeon Vincenz Czerny is credited with describing the first breast reconstruction (4). In 1893, he used a lipoma excised from the flank to restore the breast in a patient who had undergone resection of a fibroadenoma in the setting of chronic interstitial mastitis. The fat autograft was deemed successful, and Czerny noted persistence of the transplanted lipoma with a satisfactory cosmetic appearance of the breast 1 year after surgery. Since that time, however, other surgeons have found retention rates for fat grafts to be poor, especially when a large volume of tissue is transferred. Therefore, autologous fat grafting is not a viable option at the present time for total breast reconstruction.

In 1896, an Italian surgeon, called Iginio Tansini, reported using a flap of tissue from the back, which was pedicled at the axilla, to reconstruct a radical mastectomy defect (5). The publication described a skin flap that had a narrow superior base in the axilla. As might be expected, such a tissue flap was susceptible to vascular embarrassment in its most distal part, which led Tansini to more thoroughly investigate the vascular supply of these tissues. He realized the importance of including the LD muscle to make a musculocutaneous unit and published the results of this principle in 1906 (6). Although he appreciated how muscle provided soft tissue bulk to complement the skin paddle, which provided basic cover at the mastectomy site, the technique served mainly to resurface the (radical) mastectomy defect and was effectively a chest wall reconstruction, rather than a breast reconstruction per se. It was not until the 1970s that the concept of using an LD myocutaneous flap to recreate a breast mound (being complemented by a prosthesis to provide additional volume) was realized (7–9).

The silicone breast prosthesis was introduced in the early 1960s by Cronin and Gerow (10) and began to be used for postmastectomy reconstruction shortly thereafter. However, outcomes were often suboptimal owing in part to the radicalism of the extirpative surgery, which was prevalent at the time for breast cancer patients. Wide excision of skin, soft tissues, and pectoral muscle, as in Halsted's radical mastectomy, prevented adequate soft tissue coverage of the prostheses and consequently these reconstructions suffered from an esthetic point of view. The next landmark step in the evolution of breast reconstructive techniques came in 1982 with Chemodir Radovan's description of using tissue expansion prior to placement of the definitive prosthesis (11). This resulted in a larger, expanded pocket in which to place the prosthesis and also attempted to reconstruct the deficiency in the breast skin envelope following mastectomy.

Throughout the early 20th century, a number of plastic surgical techniques were used, which included flaps that were waltzed in multiple stages from a distant donor site to the defect

over a period of months (12). These fell out of favor with the emergence and better understanding of other locoregional pedicled flaps and free tissue transfer techniques that offered single-stage reconstruction.

By the 1970s, the LD flap combined with a silicone prosthesis had become a popular option in breast reconstruction. Nonetheless, this was not a completely autologous reconstruction and suffered from risks of using a foreign body such as implant infection, extrusion, and the development of peri-implant capsular contracture.

The recognition that a breast mound with overlying skin could be created with autologous tissue alone was a significant step forward and became a reality in 1982 when Carl Hartrampf (of Atlanta, Georgia, US) used abdominal tissue to reconstruct a breast mound at the mastectomy defect (13). This pedicled TRAM flap subsequently gained popularity and utilized a transverse ellipse of skin and adipose tissue along with the underlying rectus abdominis muscle, which once raised is passed through a subcutaneous tunnel to the anterior chest wall region.

Of interest, prior to this pedicled TRAM flap described by Hartrampf, Holmstrom had described the "free abdominoplasty flap" in 1979, which transferred abdominal tissue as a free tissue transfer with reestablishment of blood supply by microsurgical reanastomosis at the recipient mastectomy site (14). As microsurgery was only just emerging at the time and few surgeons possessed the necessary skills, the potential of this free flap was temporarily overlooked in favor of Hartrampf's pedicled TRAM flap.

Although a totally autologous reconstruction, the pedicled TRAM was initially plagued with complications not only at the recipient site with wound healing problems, partial flap failures, and fat necrosis but also, more importantly, at the donor site where significant rates of abdominal wall bulges and herniae occurred (15,16).

Microsurgical expertise improved with time and it was appreciated that although the rectus abdominis muscle had a dual blood supply, it was the deep inferior epigastric (DIE) vessels that were dominant in supplying the overlying abdominal skin and adipose tissue (17,18).

Consequently, the free TRAM flap based on the DIE vessels became increasingly popular for breast reconstruction. Although requiring microsurgical expertise, it resulted in lower rates of fat necrosis in the reconstructed breast but donor site problems remained similar to those for patients undergoing pedicled TRAM flap reconstructions.

The anatomy of perforating vessels from the main trunk of the DIE vessel was further delineated, and it became evident that the adipocutaneous portion of the flap could be raised on the same vessels while preserving much of the rectus abdominis muscle and rectus sheath. This description of the deep inferior epigastric perforator (DIEP) flap was arguably the most significant advance in refining abdominal flap breast reconstruction and culminated in the realization that the skin and fat of the abdomen could be harvested as a flap based solely on the perforating vessels from the DIE system. This permitted total muscle and fascia preservation, thus combining the advantages of using autologous tissue from the abdomen based on the dominant DIE system while minimizing morbidity relating to disruption of the anterior abdominal wall (19). This DIEP flap was first described in 1989 by Koshima (20), but its

specific use in breast reconstruction was first described simultaneously by Allen and Blondeel in 1994 (21,22), spawning the concept of perforator-based flap reconstructions. In a similar way, myocutaneous buttock flaps, based on the superior and inferior gluteal vascular systems, have been modified to preserve the gluteal muscles and harvest exclusively the adipocutaneous components of these flaps (23). Although there is a steep learning curve with these perforator flaps, and more prolonged initial operating times, there are clear advantages in terms of reduced donor site morbidity.

The DIEP flap, however, is technically challenging for surgeons with a definite learning period. Consequently, some surgeons prefer the “muscle-sparing TRAM (MS TRAM)” as an attempt to avoid the tedious dissection of perforators. This method includes harvesting part of the muscle around the DIEP perforators, which facilitates and shortens time for dissection, while still minimizing donor site morbidity (24,25).

#### TIMING OF BREAST RECONSTRUCTION

Breast reconstruction performed at the same time as the mastectomy is known as “immediate” breast reconstruction (IBR), and is offered routinely in many centers around the world. Indeed, the British National Mastectomy and Breast Reconstruction Audit (2) recommends that immediate reconstruction should be offered to the majority of patients undergoing mastectomy. IBR has numerous advantages (26); breast cancer resection and reconstruction are carried out under a single general anesthetic; the patient does not have to live without a breast for any time, minimizing problems with loss of femininity, body image, and self-esteem; skin-sparing mastectomy with preservation of the breast skin envelope and inframammary fold can be performed with a more esthetically pleasing reconstruction (27–29). Despite initial concerns, IBR does not compromise the adequacy of mastectomy and is oncologically safe (except in some cases of inflammatory breast cancer or where there is extensive skin involvement) (30). Although uncommon, it can potentially be associated with delay in receiving adjuvant treatments if there is prolonged healing or other problems (31). An added advantage of immediate autologous flap reconstruction is that they can better tolerate adjuvant therapies, namely external beam radiotherapy.

Delayed breast reconstruction is performed months or years after mastectomy. It has a number of potential advantages (Table 51.1), not least being the fact that cancer treatments have been completed. It also staggers surgery and entails two relatively smaller and separate procedures.

*Table 51.1* Delayed Breast Reconstruction—Advantages and Disadvantages

#### Advantages

- Stagger the surgeries: shorter recovery times
- No risk of masking recurrence
- All the adjuvant treatment has been completed

#### Disadvantages

- Difficult to achieve excellent cosmesis
- Adverse effects of prior radiotherapy
- Multiple operations, hospitalization, time off work
- Possibly more expensive overall


Meticulous planning is important for the successful execution of both immediate and delayed breast reconstruction, but factors to be taken into consideration are somewhat different for these two scenarios.

Successful immediate reconstruction also requires close consultation with the oncological surgeon. For example, in the case of an implant-based reconstruction, it is important to ensure that the mastectomy skin flaps are left adequately perfused at the end of the mastectomy prior to reconstruction. They should therefore not be too thin so as to provide viable, healthy tissue with minimal risk of poor wound healing. Necrosis of thinner mastectomy flaps may lead to wound breakdown and implant exposure. By contrast, mastectomy flaps that are too thick may contain residual breast tissue, thus rendering the mastectomy oncologically “incomplete.” Furthermore, as the prosthesis will be placed in a submuscular pocket, it is important to not violate the pectoralis major muscle during mastectomy (especially medially) as this structure is required to provide soft tissue coverage of the prosthesis. Hence, a patient who is known to have locally advanced disease with infiltration of the muscle is not a candidate for an immediate implant-only reconstruction. Another important consideration is that the breast surgeon should not disrupt the inframammary fold or indeed cross the midline during mastectomy. It is important that the breast boundaries are clearly marked on the patient preoperatively in order to guide the breast surgeon but more importantly to aid reconstruction.

Undertaking a delayed breast reconstruction can be more challenging as there may be few clues to guide the surgeon in correctly positioning the inframammary fold (if this was not preserved during mastectomy) together with the medial and lateral breast borders. Hence accurate preoperative planning is essential for a good esthetic outcome. The boundaries of the opposite breast are important in this regard. If the reconstruction is unilateral, the opposite breast will serve as a guide for preoperative marking of these critical borders. As the breast skin envelope is deficient in a delayed reconstruction (by definition), it will need to be augmented, and for implant-based reconstructions, this can be attained through a period of tissue expansion. If autologous flaps are used, the extent of skin deficiency must be calculated and incorporated into the flap planning such that the flap that is raised has an adequate skin component to compensate. It is best to overestimate the amount of skin needed.

#### IMPLANT-BASED (ALLOPLASTIC) BREAST RECONSTRUCTION

Alloplastic breast reconstruction remains the most common form of postmastectomy reconstruction (32), which is perhaps not surprising considering its relative lack of surgical complexity. Breast prostheses are available in a wide variety of shapes and sizes, with many used in breast reconstruction being biomedical nowadays. (Fig. 51.1). Anatomically, the breast prosthesis is placed in a surgically created pocket underneath the pectoralis major muscle. Careful planning is required to ensure an appropriately sized pocket is created and that it is sited in the correct anatomical position on the chest wall. As well as having a layer of partial muscle coverage for the prosthesis, it is important that the overlying skin and soft tissues are sufficiently pliable to accommodate the prosthesis. A good quality, well-vascularized soft tissue envelope will maximize the chances of primary wound



**Figure 51.1** Commonly used prostheses in breast reconstruction: (A) Natrelle™ 133 (formally McGhan® Style 133) anatomical temporary tissue expander with integrated port; (B) Mentor Siltex™ Contour Profile® temporary breast tissue expanders with integrated port—low (Style 6100), medium (Style 6200), and tall (Style 6300) height prostheses; (C) Mentor Siltex™ Contour Profile® Becker expandable implants—round (Becker 25 and Becker 50) and anatomical (Becker 35) shapes; and (D) Natrelle™ 150 (formally McGhan® Style 150) short height expandable implant.

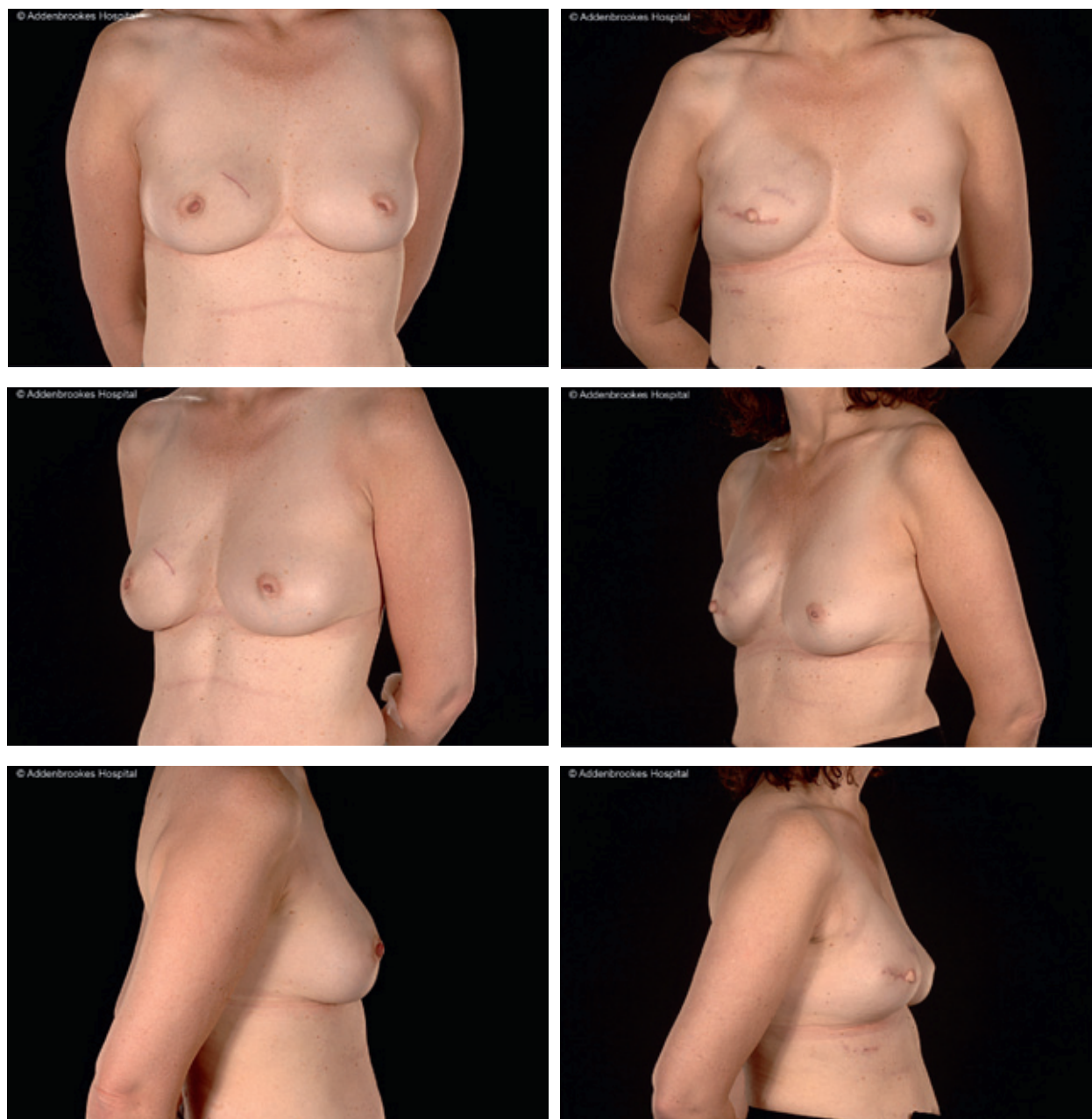healing at the postsurgical scar and will help maintain longevity of the prosthetic reconstruction. Table 51.2 lists the advantages and disadvantages of prosthetic breast reconstruction.

For the small-breasted patient, an implant-based reconstruction may be undertaken as a single-stage procedure (3,33), but patients with moderate-to-large breasts will usually require a period of tissue expansion to create a pocket of sufficient size to accommodate the definitive prosthesis and to expand the overlying breast skin envelope. Most commonly, this is achieved by placing a tissue expander in a “submuscular pocket” (deep to the pectoralis major muscle), which is inflated to the desired size over time. In a second procedure, the tissue expander is exchanged for a fixed-volume implant. Alternatively, an “expandable implant” (34), such as the Siltex® Contour Profile® Becker 35 (35,36) or the Natrelle™ 150 (formally McGhan® Style 150 (37)), can be employed. These are “hybrid” devices that, in addition to an outer silicone gel component, also have an inner inflatable pocket that can be expanded with saline to the desired size. Such

**Table 51.2** Prosthetic Breast Reconstruction—Advantages and Disadvantages

Advantages
Simple
Quick
No extra scars/no donor sites
Faster recovery
Cheaper initially: short term
Disadvantages
Small-to-moderate size breasts only
Cannot withstand radiotherapy
Complications: infection, exposure, extrusion, capsular contracture
Multistage, frequent revisions
Patient acceptance variable
Ptosis difficult to achieve
Poor projection in nipple-areola area
More expensive if combined with an acellular dermal matrix





*Figure 51.2* Right immediate implant-only reconstruction: A 49-year-old woman with grade II invasive carcinoma of the right breast underwent skin-sparing mastectomy and immediate prosthetic reconstruction with a permanent expander. No adjuvant radiotherapy was required. Postoperative images show her following nipple reconstruction, before areolar tattooing. Note the excellent reconstructive breast contour on the oblique and lateral views and the superomedial rippling. The lack of projection in the nipple areolar area is a typical feature of implant-only reconstruction. This is ideal for small-to-moderate-sized breasts with no glandular or nipple ptosis as shown here.

an expandable implant does not necessarily need to be exchanged, hence their alternative name of “permanent expanders” (3).

Any patient undergoing mastectomy is suitable for an alloplastic reconstruction (Fig. 51.2), but the technique is ideally suited to the patient with small-to-moderate-sized breasts with minimal ptosis and sufficient chest wall soft tissue to ensure adequate coverage of the prosthesis. Many patients choose to undergo this form of reconstruction as it is associated with a shorter operating time and faster postoperative recovery and does not violate another body site. This contrasts with autologous flap reconstruction where there is potential donor site morbidity. Moreover, for those patients who have a paucity of tissue or previous surgical intervention in potential donor areas,

an implant-only reconstruction may be optimal. In addition, when undergoing bilateral postmastectomy reconstruction, an implant-only reconstruction can produce a symmetrical reconstruction and is often the procedure of choice for patients undergoing bilateral reconstruction following risk-reducing mastectomies. For patients with larger breasts, prosthetic reconstruction can be feasible when a reduction of the opposite (“target” breast) is simultaneously performed.

#### **Immediate Alloplastic Breast Reconstruction**

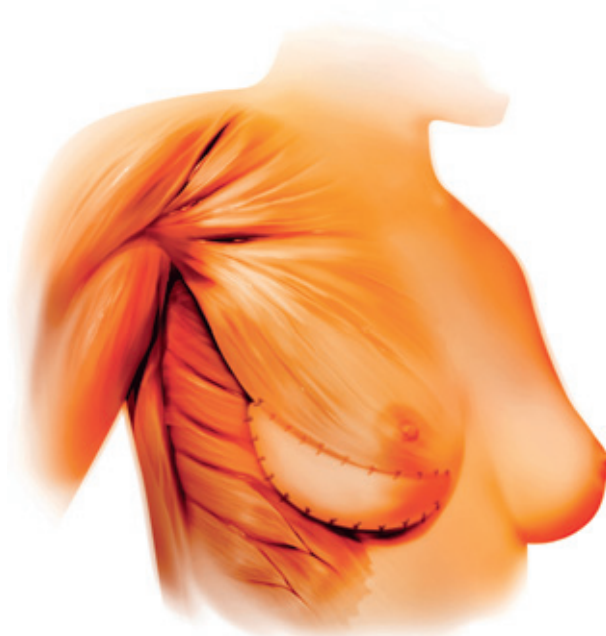Successful immediate implant-only reconstruction relies on close collaboration between the oncological and reconstructive surgeons (see Table 51.3 for indications). In this setting, the

**Table 51.3** Indications for Immediate Prosthetic Breast Reconstruction

Simple (fixed-volume) implants
Patient choice
Patient acceptance of foreign material
Small volume breasts (A/B cup size)
No ptosis
No radiotherapy planned or likely
Adequate soft tissue cover
Lack of donor tissues: primarily or secondary to previous surgery
Nonsmoker, ideally young with good muscle
Unwilling to tolerate extra scars
Bilateral reconstructions
Expanders (temporary or permanent)
Patient choice
Patient acceptance of foreign material
Small-to-moderate volume breasts (A–C cup size)
No or minimal ptosis
Lack of donor tissues: primarily or secondary to previous surgery
No radiotherapy planned or likely
Well-vascularized, healthy soft tissue and skin envelope
Unwilling to tolerate extra scars
Unfit for major surgery
Flexibility
Preferably nonsmokers
Bilateral reconstructions

mastectomy can be carried out using a skin-sparing approach with excision of the nipple-areola complex (NAC) and underlying glandular tissue and preservation of the remaining overlying skin envelope. There are many incision patterns for skin-sparing mastectomy (26–28). The incision can be drawn as a transverse ellipse to give greater access for the mastectomy and allow for a neater skin closure by eliminating “dog ears.” Once the mastectomy has been completed, the skin flaps must be assessed for their viability and the mastectomy cavity or pocket inspected for hemostasis. A submuscular pocket is then created.

- The senior author’s approach is to find the lateral edge of the pectoralis major muscle and elevate the muscle using a combination of electrocautery and blunt dissection to create the pocket. If total submuscular coverage is desired, especially in the case of thin skin flaps, an inferolateral space (deep to the serratus anterior fascia or muscle) will also need to be elevated, as the pectoralis major does not cover this area. Alternatively, if the fascia inferior to the pectoralis major muscle has been damaged or is tenuous (as in thin patients), a strip of an acellular dermal matrix (ADM), for example, Alloderm® Regenerative Tissue Matrix (RTM) or Strattice™ Reconstructive Tissue Matrix (LifeCell Corporation, Branchburg, New Jersey, USA), can be used to cover the implant in this region (Fig. 51.3).
- An alternative approach is to split the pectoralis muscle away from its lateral edge and develop a pocket from there. The advantage of this approach is that once in the submuscular plane, deep to the pectoralis major, careful dissection laterally can elevate the serratus anterior fascia and muscle in the same plane and ensure an even pocket, thus allowing total musculo-fascial coverage of the implant. This, however, can lead to poor pro-



**Figure 51.3** Illustration of Strattice™ Reconstructive Tissue Matrix *in situ* for coverage of the lower pole of the breast prosthesis (courtesy LifeCell Corporation, Branchburg, New Jersey, US).

jection but is useful in separating the implant from the axillary clearance where this has been performed. Dissection may also be more difficult.

Once hemostasis is ensured, suction drains are placed in both the submuscular and subcutaneous pockets. Care must be taken to limit the pocket to the boundaries/dimensions of the original breast, and these dimensions (the breast “foot-print”) will then govern the choice of size for the tissue expander to be used. The most important dimension is the breast width.

Patients with large breasts must be counseled that an alloplastic reconstruction is limited by the maximum size of implants available, and the reconstruction may not be able to recreate a breast of the same original size. Furthermore, implant-based reconstructions ultimately lack the ptosis associated with native tissues, and larger-breasted patients may require contralateral balancing surgery to achieve a symmetrical result (38) or possible reduction of the breast skin envelope (27,29,39).

If a small breast (A or B cup size) is being reconstructed, there may be a sufficient skin envelope to perform a single-stage reconstruction with a fixed-volume prosthesis, but similar principles in terms of choosing the most appropriate implant apply. This situation rarely occurs in routine practice. It is more applicable if the patient is undergoing bilateral breast reconstruction for very small breasts or unilateral reconstruction of the relatively larger of two small breasts.

#### **Delayed Alloplastic Breast Reconstruction**

Many patients do not undergo immediate reconstruction, either as a result of their own choice or from not being offered it at the time of mastectomy. Sometimes IBR is not available and rarely it is deemed oncologically inappropriate to undertake an immediate procedure. In such cases of delayed reconstruction, many patients choose to have an implant-only-based

technique. Selection criteria are similar to immediate implant-only reconstruction, but the main difference is the deficiency of any skin envelope and this has to be recreated. The other difference is loss of the inframammary fold and other breast borders, which is not infrequent. The site of the new inframammary fold and medial and lateral breast borders must be determined preoperatively (foot-print), and for unilateral reconstruction, the contralateral breast should serve as a template for this. To create a pocket sufficient to accommodate the definitive prosthesis, the skin and soft tissues must be surgically stretched by use of a breast tissue expander.

### Tissue Expansion

In those cases where a single-stage implant-based reconstruction with a fixed-volume prosthesis cannot be achieved, the sub-muscular pocket and the overlying soft tissue and skin envelope must undergo a period of tissue expansion, and this always pertains whenever a delayed implant-based reconstruction is being carried out. Tissue expansion is a technique that reconstructive surgeons have employed for many years, and this relies on the viscoelastic properties of skin and soft tissues and is dependent upon cellular proliferation within the stretched tissues (40,41). In 1982, Radovan successfully applied the concept to postmastectomy breast reconstruction with the use of a silicone shell implant with an expandable saline component connected via a tube to a remote port. This port was placed in a subcutaneous pocket and allowed for percutaneous injection of saline at regular intervals to inflate the prosthesis thus expanding the overlying soft tissue. Since that time, although the concept has remained the same, the devices themselves have undergone numerous modifications. Current expanders for breast reconstruction are available with either remote or integrated ports and manufactured in both round and anatomical shapes. Those with integrated ports, such as the Natrelle™ 133 (usually a butterfly needle, size 19 or 21 French gauge) (formally McGhan® Style 133) and Mentor Siltex® Contour Profile® Breast Expanders Style 6100, 6200, 6300, have a metallic backing at the port site. Hence when the patient attends the clinic, the port can be readily located by means of a magnet and a small cannula (usually a size 19 or 21G butterfly needle) accurately placed prior to expansion.

Nowadays, tissue expanders and fixed-volume implants are available in different shapes and sizes and, specific to breast surgery, these are round or 'tear-drop' shaped (bio-dimensional/anatomical/contour profile) prostheses. These latter anatomical prostheses have more volume in the inferior portion, which leads to better projection in the lower pole of the breast. The upper portion of the prosthesis is much thinner and hence the patient has a more natural looking upper pole (excessive fullness of the upper pole is often associated with the use of round expanders or implants) (3, 32).

Despite being the simplest method for breast reconstruction, implants by virtue of being prosthetic carry inherent risks (Table 51.2), which include infection and extrusion. The importance of a well-vascularized, healthy soft tissue and skin envelope is crucial to promote primary wound healing and minimize the risk of extrusion. Periprosthetic infection is disastrous for implant-based reconstruction and usually necessitates removal of the prosthesis. After some months of healing, reimplantation can be undertaken (>6 months later) once

the tissues have settled. Careful planning and a meticulous operative technique, which limits the dissection of the implant pocket to the predetermined breast borders, will minimize the risk of incorrect implant placement. Moreover, a pocket that is just large enough to accommodate the implant will reduce the chance of in-situ implant rotation or displacement.

### Capsular Contracture and the Effect of Radiotherapy on Implant-Based Reconstruction

After placement of a breast prosthesis, the body will mount a tissue reaction to it, as it is a foreign object. This results in a thin layer of scar-like tissue forming around the prosthesis, known as a capsule. In most patients, this remains as a thin layer that is neither palpable nor visible. However, in others the capsule thickens and contracts for reasons that are not entirely clear. This results in worsening degrees of capsular contracture, which Baker originally divided into four grades depending on clinical firmness of the breast following cosmetic augmentation. The Baker classification has been modified by Spear to include breast reconstruction (42), and a commonly used version is based on clinical assessment of the breast capsule, as follows:

- (I) impalpable, not visible;
- (II) palpable, not visible;
- (III) palpable and visible; and
- (IV) causing symptoms, such as pain, often associated with visible distortion of the breast.

Severe capsular contracture (grade III/IV) typically requires revisional surgery in the form of capsulectomy and implant exchange.

The reasons for development of severe capsular contracture in patients with breast implants have not been fully elucidated. However, the incidence appears to be influenced by pocket location (submuscular placement is associated with lower rates) and implant surface (textured implants have lower rates compared with smooth implants) (43,44). Furthermore, subclinical infection and hematoma formation have also been implicated as causative factors, and most notably in breast reconstruction significantly increased rates are seen in patients receiving external beam radiotherapy as part of cancer treatment. In the authors' unit, a review of patients having immediate prosthesis-based breast reconstructions suggested a 30% incidence of severe (grade III/IV) capsular contracture at 5 years in patients undergoing postoperative radiotherapy compared with those without radiotherapy for whom the incidence of severe capsular contracture was zero (45). These risks need to be discussed with patients who are likely to require postoperative radiotherapy (e.g., those with locally advanced or aggressive tumors or those at a risk of local or regional recurrence following mastectomy), and close liaison with the oncologist and breast surgeon is essential. In such patients, it is often more appropriate to avoid an implant-based reconstruction and instead carry out an immediate reconstruction using autologous flaps. If none of these are suitable or acceptable to patients, a delayed reconstruction is preferable.

Similarly, preoperative radiotherapy can have deleterious effects on the native tissues of the breast with induction of perivascular inflammation leading to endarteritis obliterans in the skin and soft tissues. This results in reduced tissue vascularity and is associated with high rates of complications such



**Table 51.4** Indications/Advantages of Autologous Tissue Reconstruction

Patient choice
Large or ptotic breasts
Adjuvant radiotherapy is planned: can tolerate postoperative radiotherapy
Previous radiotherapy
Best possible cosmetic result is demanded by the patient
Most durable and natural
Best cosmesis
No artificial materials

as poor wound healing, skin necrosis, infection, and implant extrusion (46,47). For these reasons, the use of implants in patients who have had previous radiotherapy may not be appropriate, unless supplemented by autologous flaps, such as the LD myocutaneous flap, which will bring in healthy, well-vascularized tissue to aid primary healing, and these discussions must be had with patients before choosing the mode of reconstruction. In previously irradiated patients undergoing implant-based reconstruction, it is important that the expander is minimally filled at surgery and the inflation protocol is more protracted (start later, i.e., at 3 weeks, and inflate with small volumes and less frequently).

#### AUTOLOGOUS TISSUE BREAST RECONSTRUCTION

The main indications for autologous tissue breast reconstruction are listed in Table 51.4, most of which are relative. Autologous tissue is generally more durable than prosthetic material and results in a more natural looking breast. The use of autologous tissue provides opportunity to avoid artificial materials. Furthermore, they provide versatility in creating ptosis, the anterior axillary fold, lateral fullness, and filling out the infraclavicular hollow. These aspects of breast reconstruction are much less likely to be achieved with a prosthesis-based reconstruction.

The critical issues in selecting one technique (Table 51.5) over another are beyond the scope of this chapter but briefly include (i) patient's choice, (ii) availability of donor tissues (patient body habitus), (iii) recovery period, (iv) likely requirement for adjuvant radiotherapy, (v) the presence of previous scars, and finally, (vi) the surgeon's experience and preference. Implant-based reconstructions should generally be avoided in patients for whom radiotherapy is planned (45).

#### THE LD MYOCUTANEOUS FLAP

The LD is a large flat muscle that has a proximal attachment (insertion) to the floor of the bicipital groove of the humerus and has distal attachments (origins) to the angle of the scapula, spinous processes of lower thoracic vertebrae and integrates with the lumbar fascia at the level of the posterior iliac crest. The vascular pedicle is the thoracodorsal vessels from the subscapular axis, and this enters the muscle 8 cm (roughly a hand's breadth) below the axilla. During flap harvest, it is essential to be conversant with the vascular anatomy of this area to ensure flap viability. This is also of particular importance when the patient is undergoing, or has undergone, axillary dissection, as the thoracodorsal vessels are encountered in this surgery. This is also of relevance to immediate reconstruction in the lateral position when the flap is being harvested with the patient on

**Table 51.5** Main Types of Autologous Tissue Reconstruction

Latissimus dorsi myocutaneous flap
Abdominal flaps
Pedicled transverse rectus abdominis myocutaneous (TRAM) flap
Free TRAM flap
Deep inferior epigastric artery perforator (DIEP) flap
Superficial inferior epigastric artery (SIEA) flap
Gluteal flaps
Superior gluteal myocutaneous flap
Inferior gluteal myocutaneous flap
Superior gluteal artery perforator (SGAP) flap
Inferior gluteal artery perforator (IGAP) flap
Taylor-Ruben's peri-iliac flap
Thigh flaps
Transverse upper/myocutaneous gracilis flap (TUG/TMG)
Lateral transverse thigh flap
Anterolateral thigh (ALT) flap

their side. Under these circumstances, some reconstructive surgeons themselves identify it for the ablative surgeon.

When designing an LD flap, a skin paddle needs to be harvested with the muscle. For immediate reconstruction following skin-sparing mastectomy with a periareolar incision, this will reconstruct the area where the NAC has been removed. In the case of a delayed reconstruction (Figure 51.4B), a larger skin paddle is required. Various designs of skin paddle have been described, but the authors prefer to draw a transverse skin paddle at such a location where there is sufficient skin excess so that tension-free primary closure can be achieved. It is preferable to place the resultant scar in the brassiere line (as shown in Figs. 51.4A and 51.4B), with the aim that it will be concealed when the patient is wearing a brassiere or swimwear. In delayed reconstruction where a large skin paddle is needed, or in a totally autologous LD reconstruction, the skin paddle is orientated obliquely in the crease line in order to allow a wider skin paddle to be harvested (maximum width of about 10 cm).

For immediate reconstruction (Figure 51.4A), it is possible to perform mastectomy and/or axillary clearance at the same time as the flap is being raised, with the patient placed in the lateral decubitus position. If a skin-sparing mastectomy is being undertaken, a small skin paddle on the LD muscle will be required to reconstruct the skin defect in the breast envelope. Careful planning is required to ensure the skin paddle of the flap is sited such that it will inset appropriately at the recipient site. Nonetheless, the exact position may be less critical when division of the LD tendon is carried out, which allows greater flexibility in terms of flap positioning and inset. In the case of a delayed reconstruction (Fig. 51.4B), a larger skin paddle is required, the length of which should approximate to the width of the breast to be reconstructed. The vertical width of the skin paddle should not be excessive and allow primary closure of the back wound. Although a larger skin paddle will be required in a delayed reconstruction, skin from the back alone may be insufficient to fully reconstruct the breast skin envelope. In these circumstances, the skin can be further increased in extent by the use of a tissue expander. In contrast, in immediate reconstruction, a fixed volume (standard) implant may sometimes be used.

In the case of delayed reconstruction, the mastectomy scar on the anterior chest will need to be excised with elevation



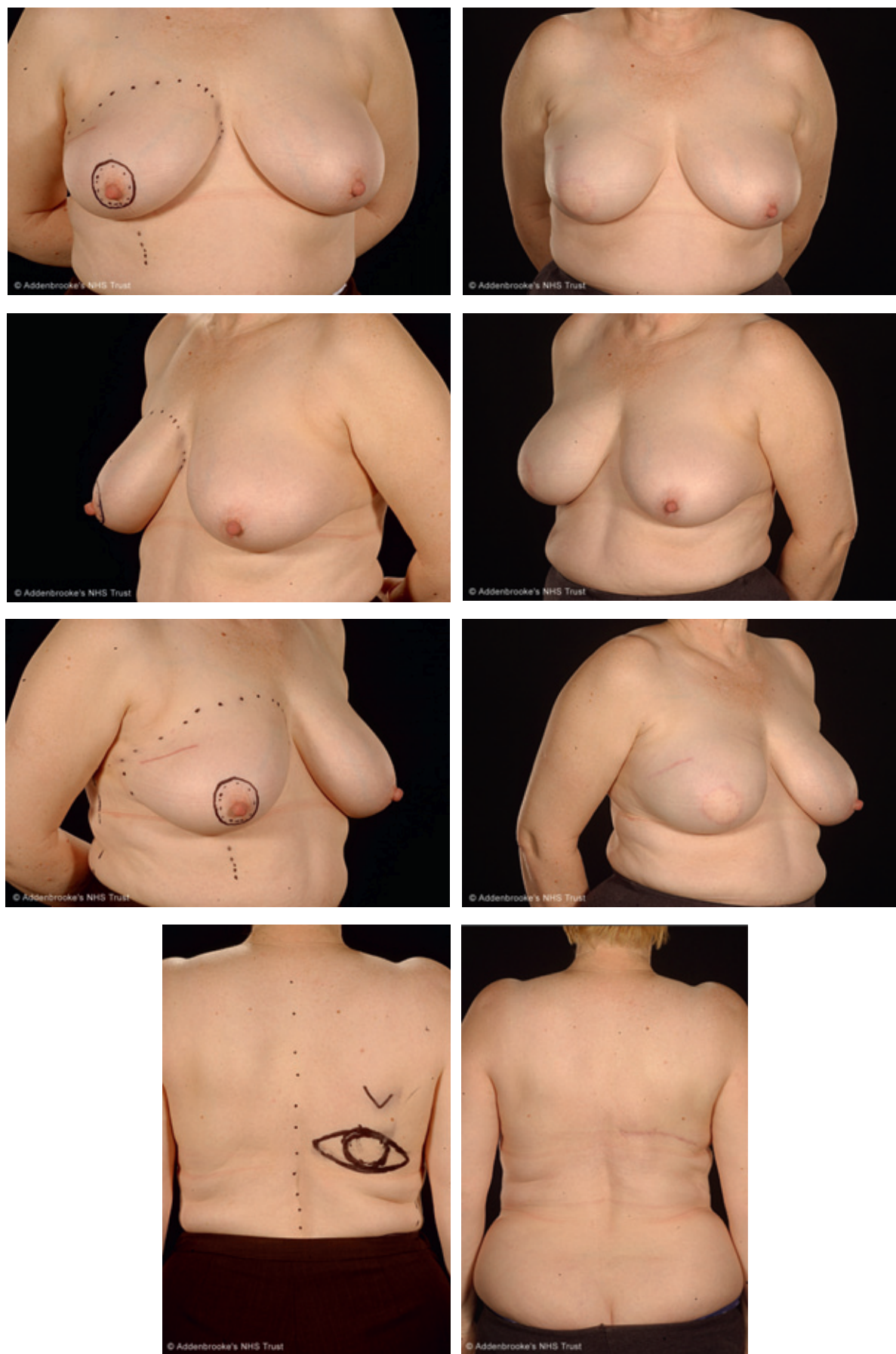
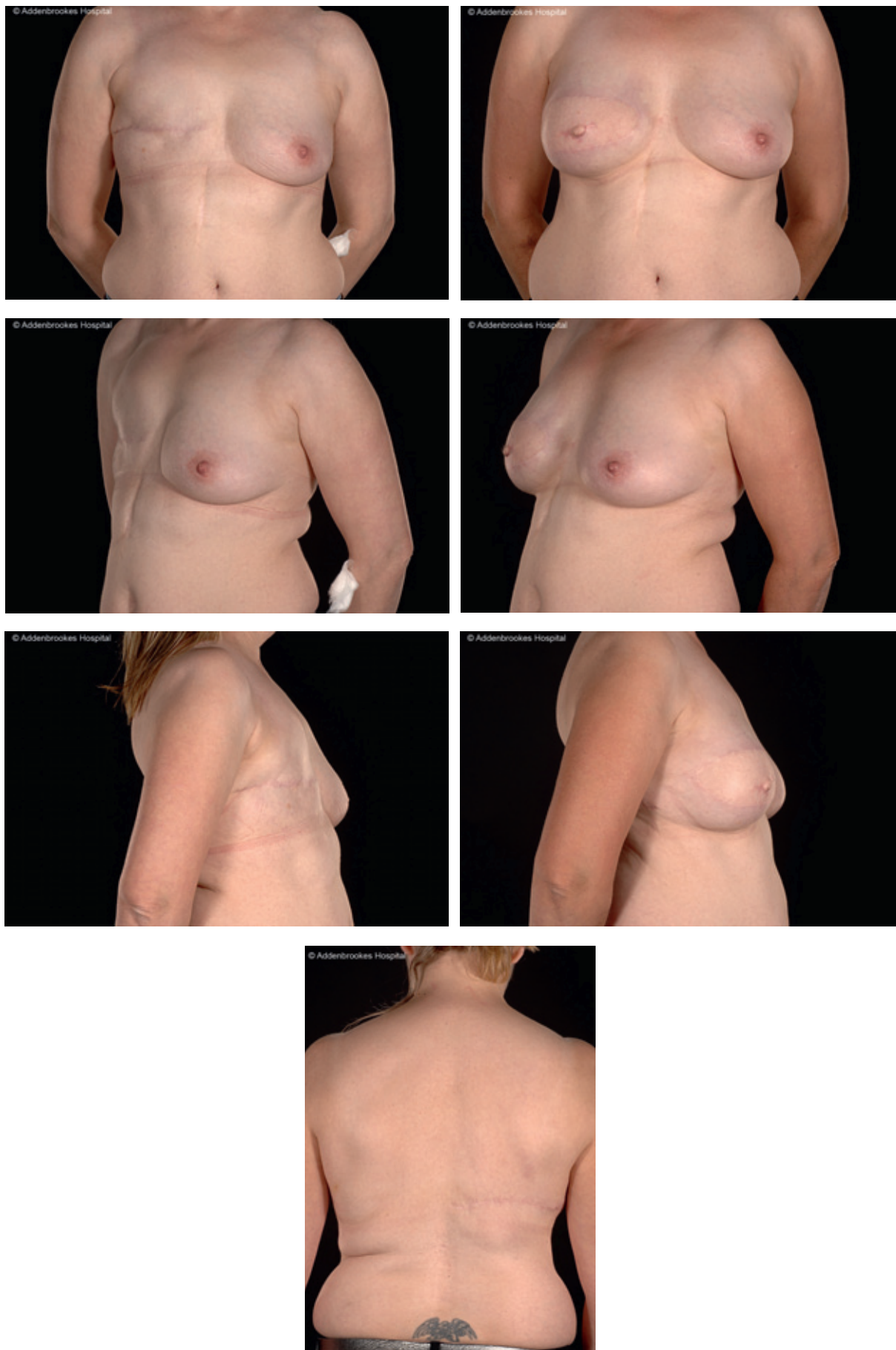


Figure 51.4A LD flap immediate breast reconstruction: A 57-year-old woman with previous lumpectomy of the right breast had a right skin-sparing mastectomy for DCIS with immediate reconstruction with an LD flap and expandable implant. This patient declined nipple reconstruction. The LD skin paddle is orientated horizontally so as to leave a scar that can be hidden in the brassiere line. Note the moderately large-sized and ptotic breasts that were successfully reconstructed with this technique. Abbreviations: DCIS, Ductal carcinoma *in situ*; LD, Latissimus dorsi.



*Figure 51.4B* LD flap delayed breast reconstruction: A 48-year-old woman who underwent a delayed reconstruction of the right breast with an LD myocutaneous flap and tissue expander, 12 months after her mastectomy. The delayed option requires a larger skin paddle to be taken, as shown in this patient. The downside of delayed breast reconstruction with autologous flaps is the obvious patch effect. *Abbreviations:* LD, Latissimus dorsi.

of mastectomy flaps such that a pocket is surgically created to allow inset of the flap. The LD flap is transferred to the site of the mastectomy defect through a subcutaneous tunnel high in the axilla, and care must be taken to ensure the vascular pedicle is not placed under any tension, kinked, twisted or avulsed during this maneuver (48). Adequate perfusion of the flap should be checked at this stage. Transposition of the flap can be aided by dividing the proximal tendinous attachment, and this allows for greater flexibility in movement and inset of the flap (49) and possibly improved cosmetic results (50).

A standard LD myocutaneous flap alone will generally not provide sufficient tissue to completely reconstruct the volume deficit following the mastectomy. There are two ways in which satisfactory volume replacement can be achieved. First, a “total autologous” or “extended” LD flap can be used (51,52). Six areas of fat are potentially available to safely harvest with the LD flap, but this extended technique is only suitable for selected patients. These fatty zones are as follows:

1. Fat deep to the skin paddle
2. A layer of fat below the superficial (Scarpa's) fascia covering the entire surface of the muscle
3. Suprascapular fat
4. Fat adjacent to the anterior edge of the flap
5. Suprailiac fat (so-called love handles)
6. Fat on the deep surface of the muscle.

This technique is suitable for patients who have an excess of adipose tissue in the region of the back but is very much dependent on individual body habitus.

The method for additional volume replacement that is most commonly used, however, is to supplement the LD flap with a prosthesis—an implant-assisted LD flap. Once the flap is transposed and the LD muscle has been inset to the periphery of the predetermined breast borders, the prosthesis (expander or implant) is placed deep to it. In the case of an immediate reconstruction of a small breast, this can be achieved using a fixed-volume implant. In the case of delayed reconstruction or immediate reconstruction of a larger breast, tissue expansion may be required and similar principles to implant-only reconstruction with tissue expanders or expandable implants apply. The volume of an LD flap based reconstruction can also be increased by the use of fat injections (performed either at the same time or later) (53).

Vascular compromise or total failure of an LD flap is very unusual. If it does occur, it may be due to unrecognized injury to the vascular pedicle, excessive tension on the pedicle, or inadvertent twisting/kinking. Hence careful transposition of the flap from the back to the anterior chest wall, ensuring the pedicle is lying tension free without any twists or kinks, is essential to minimize these potential problems. The tunnel must be adequate and must not have a “sharp” edge over which the pedicle may be stretched or kinked. Sometimes if an expander filled with saline has been used, the pressure of the filled prosthesis may be sufficient to produce external pressure on the flap's pedicle. This can be relieved by removing fluid from the injection port in the immediate or early postoperative period.

One of the more common sequelae of LD flap harvest is the potential space that is left behind at the donor site; it is not uncommon for patients to develop seromas that require serial needle aspiration postoperatively. The use of suction drains

may reduce the incidence of seroma formation to some degree, and other measures such as quilting of the donor site at the time of wound closure may also help (54).

Limitations of shoulder function following LD flap breast reconstructions are reported, but early postoperative physiotherapy can help minimize these functional problems (55). Although certain groups of patients rely on the function of the LD muscle (such as wheelchair-bound patients or those who undertake activities such as rock climbing (56)), for the majority of patients, the remaining stabilizing muscles are sufficient to avoid any compromise in shoulder function. However, these factors must be borne in mind when counseling the young, physically active female patient who is being considered for breast reconstruction. These effects may be compounded when undergoing a bilateral LD-based reconstruction, leading to a synergistic deficit in function (57).

Overall, the LD muscle is an extremely reliable flap for breast reconstruction with an anatomically consistent, robust blood supply and a low incidence of significant long-term donor site morbidities. It is useful in the setting of both immediate and delayed breast reconstruction. As often used in conjunction with a prosthesis, the LD flap provides total muscular coverage of the implant, which is effectively sandwiched between two well-vascularized muscles, namely the pectoralis major below and the LD muscle above. This anatomical arrangement maximizes the opportunity for primary wound healing, and possibly reduces capsular contracture rates.

#### ABDOMINAL FLAPS

Abdominal pedicled and free flaps are based on blood vessels that supply the rectus abdominis muscles and the overlying adipocutaneous tissue. In addition to this, the lower abdominal skin and fat also receive blood supply from the superficial inferior epigastric (SIE) system, which derives from the femoral vessels.

The rectus abdominis muscles are a paired set of muscles that are vertically oriented either side of the midline, from the xiphisternum to pubis. The rectus abdominis muscle has a dual blood supply. Superiorly this is from the superior epigastric artery (a continuation of the internal thoracic artery) and inferiorly from the deep inferior epigastric (DIE) artery, a branch of the external iliac artery. These vessels enter the deep surface of the muscle, and their terminal branches anastomose with each other. From these deeper vessels, small perforating blood vessels traverse the rectus abdominis muscle and enter the overlying skin and adipose tissue, creating a network of vessels that connect across the anterior abdominal wall. An understanding of this intricate vascular network is essential in the planning and execution of the TRAM, SIEA and DIEP flaps.

#### The Pedicled TRAM Flap

The pedicled TRAM flap (13) is based on the superior epigastric vessels and uses a transverse adipocutaneous paddle (as would be removed during an abdominoplasty) attached to the rectus muscle to recreate the breast. Once raised, the flap is passed through a subcutaneous tunnel in the hypogastrium to the breast and inset into the mastectomy defect (Fig. 51.5A). It is important to position the muscle pedicle carefully without kinking it. Since its original description, the pedicled TRAM flap has been associated with significant complications, both at donor and at recipient sites. At the donor site, removal of one of the



rectus abdominis muscles and its attached rectus sheath leaves a defect that typically requires a synthetic mesh to reestablish the integrity of the anterior abdominal wall. This carries the inherent risk of hernia formation, but with meticulous technique during inset of the mesh and closure of the abdominal donor site, the development of bulges and herniae can be reduced and any functional compromise minimized (58). At the site of the flap inset, partial flap necrosis in the early postoperative period has been described, while late fat necrosis tends to occur at the periphery of flaps in those areas farthest away from the vascular pedicle (59). These areas of fat necrosis lead to suboptimal final results (60).

### The Free TRAM and DIEP Flaps

Improvements in abdominal flap breast reconstruction came about with realization that the adipocutaneous component of the TRAM flap was better perfused by the perforating vessels that arise from branches of the deep inferior epigastric (DIE) vessels. A flap based on these vessels, however, necessitates the use of microsurgery to vessels at the recipient site. This refinement of the TRAM flap had a steep learning curve but successful free flap transfer resulted in improved outcomes at the recipient site (Fig. 51.5A). Nonetheless, a free TRAM flap still harvests a portion of the rectus abdominis and rectus sheath with continued risk of donor site problems. Further refinements came with improved understanding of the anatomy of DIE perforators, and how the flap could be raised as an adipocutaneous unit with only a small amount of muscle (the so-called MS TRAM flap) (24) or even without the need to sacrifice any of the rectus muscle or rectus sheath at all (DIEP flap) (Figs. 51.5B–C) (21,22). It should be noted that even if the muscle bellies are left intact, the nerve supply to the rectus abdominis muscle must be protected to minimize functional loss.

When dissecting the perforators through the rectus abdominis muscle, often a split in the muscle along the line of its fibers is all that is necessary to visualize and further dissect the perforators. However, anatomy of these perforating vessels is variable. The DIE vessels can have one of three arrangements (61). Most commonly, the vessel divides into medial and lateral trunks and perforators arise from these. Lateral row perforators tend to have a shorter, more vertical route through the muscle, whereas medial row perforators (although often of a larger caliber) tend to have a more oblique and longer intramuscular course, necessitating more dissection. The other two anatomic variations are the presence of only one trunk or existence of three trunks. Regardless of type, these trunks gradually decrease in size as they travel superiorly and will eventually anastomose with branches of the superior epigastric system.

Once the perforators are identified, dissection will proceed in an inferior direction, and the main trunks will be followed back to the DIE vessels. After the recipient site vessels have been prepared, the DIE artery and vein can be ligated and divided prior to reanastomosis at the recipient site mastectomy defect.

From the surgical viewpoint, the transverse ellipse of skin and fat that makes up the flap is divided into four zones as originally described by Hartrampf, although this classification has been subsequently modified following emergence of the DIEP flap (62). The area overlying the pedicle is termed zone 1,

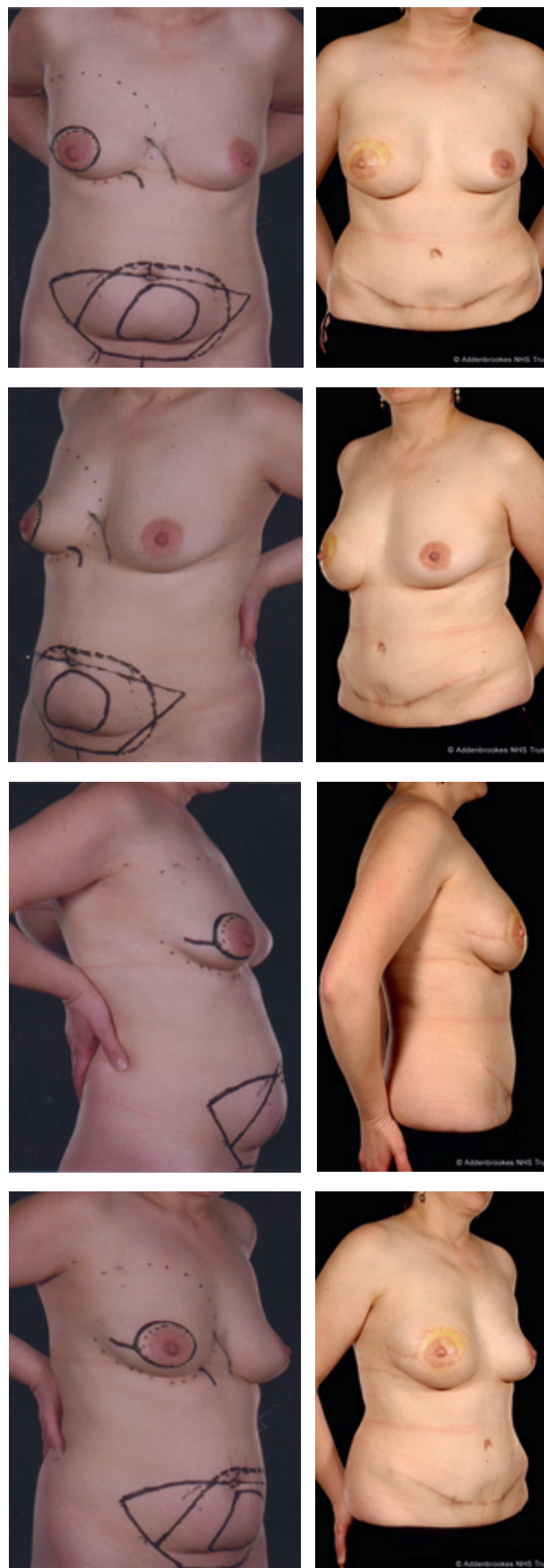
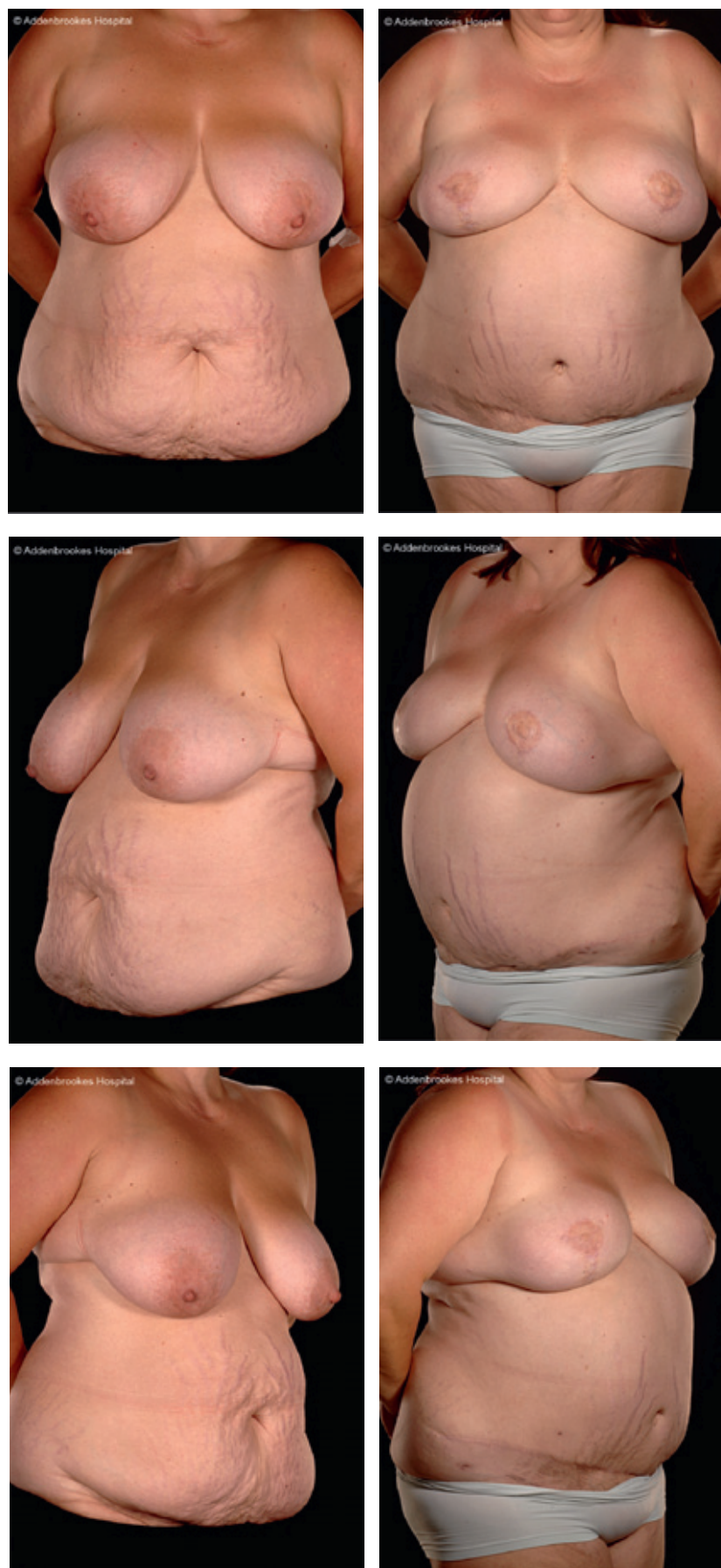
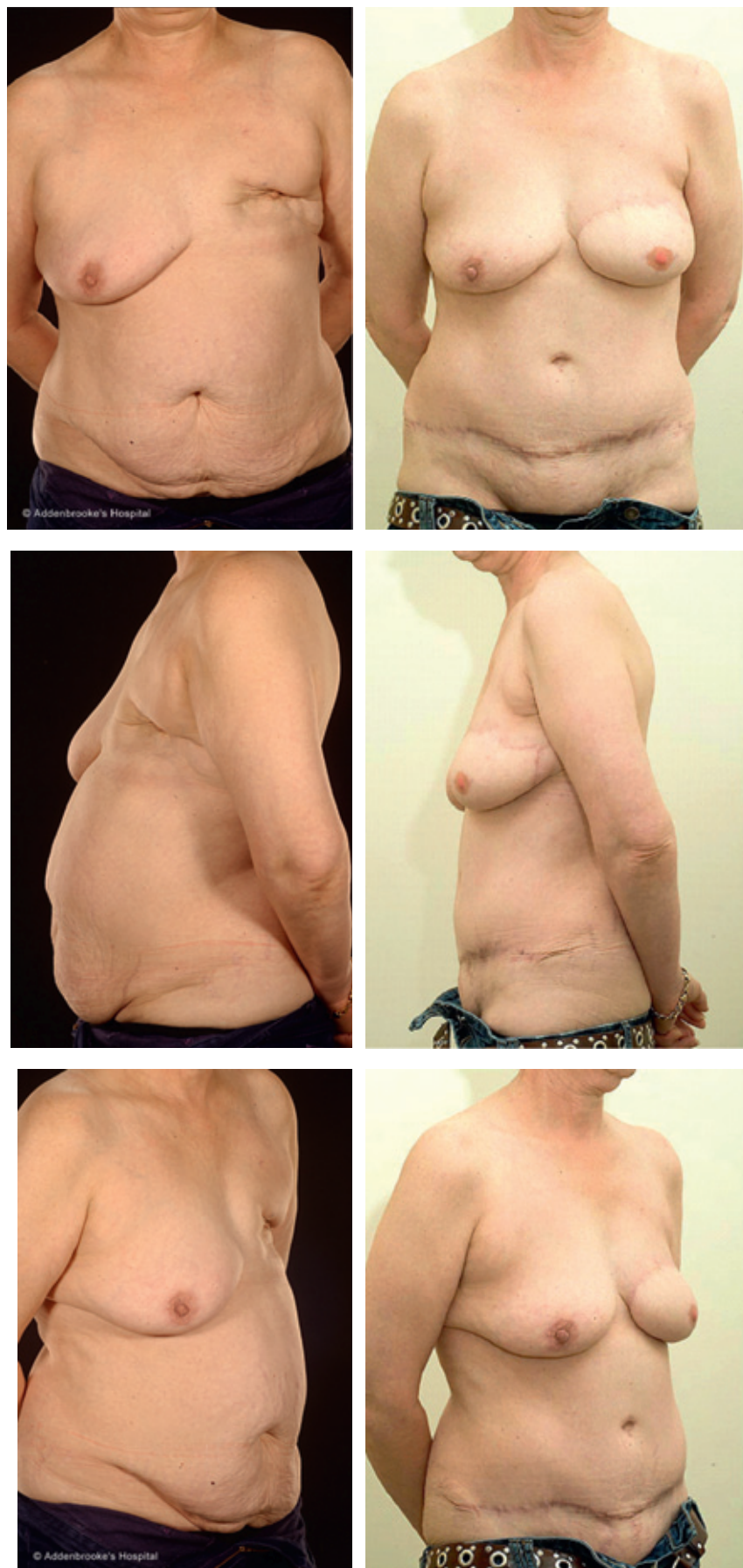

Figure 51.5A Abdominal flap reconstruction: A 41-year-old woman who underwent a right-sided skin-sparing mastectomy with immediate left pedicled TRAM flap reconstruction of the right breast. The position of the subcutaneous epigastric tunnel is shown between her breasts in the preoperative images. The tumor dictated a large skin resection and replacement, hence the target-like appearance of the right breast following nipple-areolar reconstruction. Abbreviation: TRAM, transverse rectus abdominis myocutaneous.



*Figure 51.5B* Abdominal flap immediate breast reconstruction: A 49-year-old woman with Cowden's syndrome and large ptotic breasts elected to proceed with bilateral risk-reducing mastectomies, which were performed using the LeJour skin reduction pattern and reconstructed using a DIEP flap for the right breast and an SIEA flap for the left breast. The postoperative breast mounds show an improvement in appearance, mimicking an esthetic breast procedure, without sacrificing breast volume or symmetry. *Abbreviations:* DIEP, deep inferior epigastric perforator; SIEA, superficial inferior epigastric artery.





*Figure 51.5C* Abdominal flap delayed breast reconstruction: A 58-year-old woman with a severe postmastectomy and postradiation deformity presented for delayed breast reconstruction. Despite the small breast volume, she declined implant-based reconstructions. She therefore underwent a free DIEP flap to the left breast with excellent cosmesis. The abdominal flap was able to restore the chest contour and addressed the large skin deficit. Postoperative results after NAC tattoo. **Abbreviations:** DIEP, deep inferior epigastric perforator; NAC, nipple-areola complex.



whereas the zone farthest away from the pedicle is zone 4. The areas of the flap nearest to the pedicle are often best vascularized, usually some or all of zone 4 has to be discarded as it will be relatively poorly vascularized in comparison. Depending on which specific perforators are chosen to base the flap on, be it lateral or medial rows, zones 2 and 3 are either ipsilateral or across the midline, respectively. Therefore the nomenclature is interchangeable depending on the precise vascular anatomy of the flap.

The free TRAM and DIEP flaps utilize the same abdominal tissue as used in Hartrampf's original pedicled TRAM flap, which corresponds to the tissue that is removed during an abdominoplasty or apronectomy operation. Hence if a patient has undergone either of these procedures in the past, this precludes a free TRAM/DIEP flap. Furthermore, if there has been any previously documented injury to the DIE vessels, then likewise this flap should not be attempted. If such an injury is suspected (e.g., from previous trauma or surgery), it may be pertinent to undertake radiological imaging of these vessels even though successful flap harvest is possible in patients with pre-existing abdominal scars (63,64). In fact, because of the variability of the specific DIE perforators, many surgeons choose to routinely carry out radiological imaging of the DIE and its perforators prior to surgery. Not only does this confirm the presence of the main trunks but also provides a roadmap of the perforators, which allows judgment on which are the best perforators to be utilized in the flap. This can be done using one of the several imaging modalities—duplex sonography, CT, or MR angiography (65).

#### **The Superficial Inferior Epigastric Artery Flap**

In some cases, especially those in which only half of the abdominal tissue is required, a flap based on the superficial inferior epigastric (SIE) vessels can be raised (66,67). The SIE vessels typically supply the ipsilateral skin and fat only and therefore flaps based solely on these vessels cannot reliably cross the midline (68). However, the caliber of these vessels, in particular the superficial inferior epigastric artery (SIEA), is highly variable and often of insufficient size to be reliably dissected. Indeed, anatomic and clinical reviews suggest that the artery is useable in fewer than 50% of dissections (17,69). In those patients where a sizable or prominent SIEA and vein are identified during flap harvest surgery, the flap can be raised without disruption of the rectus sheath (Fig. 51.5B), but it must be remembered that vascularity across the midline is not guaranteed, and consequently only half of the lower abdominal skin and fat can be safely harvested. The limiting factor from a technical viewpoint is the size of the artery; if it is pulsatile and clearly visible without (surgical) loupe magnification, it is possible to harvest the flap. It is the senior author's practice to look for the SIE vessels in every patient undergoing lower abdominal flap breast reconstruction in case the artery is large enough to support a flap. However, an SIE artery flap is not formally planned at the outset, except in patients who have lost significant amounts of weight (70).

The SIE vein can also prove useful if present and can be dissected to provide additional venous drainage for a TRAM or DIEP flap. Therefore, routine preservation of the SIE vein is recommended (71).

#### **ALTERNATIVE FREE FLAP RECONSTRUCTIONS**

If a patient declines a prosthesis-based reconstruction, and it is decided to proceed with a flap-based reconstruction, there will be instances where the first choice of an abdominal free flap is not available or tissue volume is insufficient for the size of reconstruction required. In these circumstances, alternative donor sites can be considered.

Flaps raised from the buttock area are based on blood supply from the superior and inferior gluteal vessels. Before development of the perforator concept, these flaps were raised as musculocutaneous units, taking portions of the gluteus maximus muscle with it (72,73). This can potentially result in morbidity at the donor site, which might be manifest as problems with gait, for example. However, the main problem with the gluteal myocutaneous flaps was the reach of the pedicle. It was shortened by the presence of muscle and often vein grafts were needed (72,73). The shorter vascular pedicles also hindered flap inset as the recipient site routinely used at that time was the thoracodorsal vessels. When raised as perforator flaps, there is no muscle to sacrifice with consequent advantages of fewer donor problems and longer pedicles. The superior gluteal artery perforator (SGAP) flap harvests tissue from the upper part of the buttock (74), whereas the inferior gluteal artery perforator (IGAP) flap uses tissue from the lower buttock (75). The IGAP flap is often preferred because of better scarring and lower donor site deficit. With particular regard to the reconstruction, buttock tissue tends to be firmer than abdominal tissue, and although providing more projection than a DIEP/TRAM flap, the tissue is more difficult to shape. At the donor site, the SGAP flap leaves a conspicuous scar across the upper buttock and can leave a flattened or depressed contour. In contrast, the IGAP flap can be harvested in such a way so that the donor scar is placed in the lower gluteal crease (75). Criticisms of gluteal flaps include difficulty in simultaneously harvesting the flap and performing mastectomy for immediate reconstruction due to patient positioning, difficult perforator dissection, constrained flap inset and potential buttock asymmetry.

If a patient's body habitus is such that they have minimal abdominal or buttock tissue, an alternative flap option is the transverse upper/myocutaneous gracilis flap (76,77), which utilizes adipocutaneous tissue from the upper medial thigh and the gracilis muscle. The gracilis is a thin, long muscle in the adductor compartment of the thigh whose arterial supply arises from the adductor artery, a branch of the profunda femoris. Harvest of the muscle leaves minimal donor site morbidity. This flap is particularly useful when carrying out reconstruction of a small breast, although problems with donor site healing are reported (78).

#### **MISCELLANEOUS ASPECTS OF BREAST RECONSTRUCTION**

##### **Free Flap Microsurgery**

###### *Recipient Vessels*

The authors' preferred choice for recipient vessels in free tissue breast reconstruction is the internal thoracic (internal mammary) vessels. The traditional technique for preparing these recipient vessels is to remove the third costal cartilage and prepare the vessels between the second and fourth costal

cartilages (79,80). However, a cartilage-sparing approach is preferred (81), and the vessels can be prepared without excising any costal cartilage (82).

If the internal thoracic vessels are not available, options include the thoracodorsal or circumflex scapular vessels in the axilla and indeed these are the vessels of choice for many reconstructive surgeons (83,84). The disadvantage is that microsurgery has to be performed in the axillary region and hence an adequate length of pedicle is required. If the pedicle is short, as in a SIE artery flap, the thoracodorsal vessels may not be appropriate; however, with DIEP flaps, pedicle length is not an issue and microsurgery can be carried out at either recipient location.

#### *Perioperative Management*

Successful free flap breast reconstruction is not only reliant on factors associated with surgery per se, but careful preparation of patients and postoperative management are essential. Surgery involves prolonged general anaesthesia, and hence a patient's comorbidities and their suitability for a free flap procedure must be assessed. Flap planning involves selecting the most appropriate flap for individual patients, and adjuncts such as the handheld Doppler, duplex sonography, or angiography (CT/MRI) can be used to evaluate perforating vessels in the flap being planned.

Intraoperatively, careful dissection and meticulous tissue handling are necessary to avoid mechanical and thermal damage to the delicate blood vessels that will perfuse the flap. Once raised, microsurgery to reanastomose the flap's pedicle to recipient vessels must be undertaken with a precise technique to ensure successful flap perfusion. A suboptimal microsurgical technique will encourage thrombus formation at the site of the anastomosis, which can lead to flap failure.

Postoperatively, these patients must be nursed in heated rooms (>70°F) and be kept well hydrated (to ensure maximal perfusion of the flap) and also pain free to minimize sympathetically driven vasoconstriction. Regular assessment with accurate recording of respiratory and hemodynamic parameters is essential for optimal recovery; oxygen saturation, respiratory rate, pulse rate, systemic blood pressure, temperature, and hourly urine output measurements must all be recorded. Any deviation from normal values or changes in trends should be identified and acted upon promptly. An accurate, noninvasive measure of fluid balance in patients undergoing free flap surgery is urine output, which should be a minimum level of 0.5–1 ml/kg/hr to maintain hyperdynamic circulation within the flap.

#### *Free Flap Monitoring*

Monitoring perfusion of the free flap is absolutely vital for early detection of any signs that indicate a failing flap. Clinical assessment is one of the most accurate and reliable methods but must be carried out by trained nursing staff. Clinical signs that are readily assessable on inspection include the color and capillary refill times. Palpation of the flap will allow assessment of temperature and turgor as well as the presence of swelling or hematoma, either of which could cause external compression of the flap's pedicle, especially the vein. As these flaps contain perforating vessels that reach the skin, clinical assessment can be supplemented by the use of a handheld Doppler probe to auscultate arterial and venous signals from the perforators.

The skin paddle of a healthy flap will be of normal color (relative to donor site skin), be soft and warm to the touch, and have a capillary refill time of approximately 2 seconds. By contrast, a pale, flaccid skin paddle with a delayed capillary refill time and which fails to bleed if scratched with a needle suggests impaired arterial inflow. A problem with the venous outflow may be evident from a mottled appearance, swelling, and increased turgor in the presence of a brisk capillary refill time. When scratched, a flap with a venous congestion will rapidly ooze dark blood. A common cause for flap congestion is external compression of the pedicle vein by hematoma. Tight dressings may also contribute to external compression of the pedicle, and the initial maneuver is to release dressings and sutures, which may provide relief. Any suspicion of a failing flap should prompt immediate surgical exploration to maximize the chance of salvage. The patient must return to the operating theater without delay for examination of the microanastomoses and flap pedicle. If necessary, the microsurgical anastomoses will need to be redone, and the earlier this intervention is carried out, the higher is the chance of the flap surviving.

Free flap failure is generally uncommon with the latest figures from the United Kingdom (UK) National Mastectomy and Breast Reconstruction Audit (2), suggesting that the national rate for complete flap failure is 2%. To maximize success rates with this surgery, it should only be undertaken in units well rehearsed in the care of these patients, where microsurgery is carried out on a regular basis and where systems are in place to identify and manage postoperative problems quickly and efficiently.

#### **Acellular Dermal Matrices (ADMs)**

In patients with moderately large breasts or those with poor soft tissue coverage, an alternative to using a LD flap with a prosthesis is to use an Acellular Dermal Matrix (ADM), such as Alloderm® Regenerative Tissue Matrix (RTM) or Strattice™ Reconstructive Tissue Matrix, human- and porcine-derived biosynthetic materials respectively." (Fig. 51.5) (85–87).

These materials can be used to provide coverage and support to the lower pole of the breast prosthesis. By creating a pocket underneath the pectoralis major (starting from its lateral edge rather than splitting the muscle as mentioned above), the superomedial part of the prosthesis will be covered. Instead of elevating some of the serratus anterior fascia or muscle to provide inferolateral coverage of the prosthesis, the ADM can be sutured to the periphery of the defect in this lower pole and acts as a sling to cover and provide support and coverage for the prosthesis. The other edge of the ADM sheet is sutured to the free lateral edge of the pectoralis major muscle, thereby totally covering the prosthesis. The material acts as a scaffold into which there is vascular ingrowth, shown experimentally (88) and clinically (89), and with time the material is said to incorporate with the native tissue. The advantage over trying to achieve total submuscular coverage under serratus inferolaterally is that the breast can have a more natural, ptotic appearance and the projection will not be constrained by a submuscular pocket, which would otherwise lack ptosis and projection. However, the material is thinner than muscle and is initially avascular, requiring time for the vascular in growth. The significant cost associated with these products also needs to be factored into decision making.

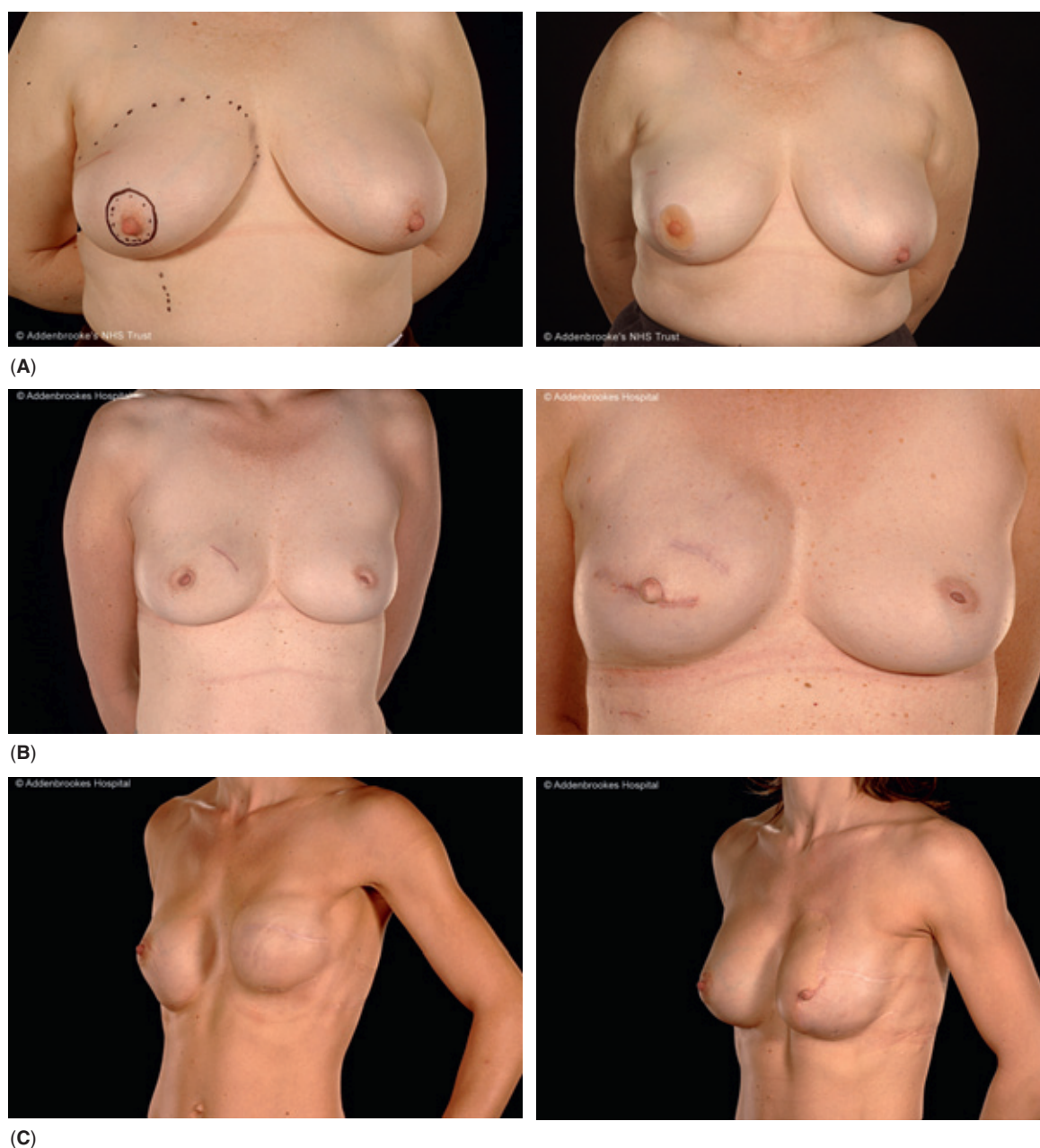


Figure 51.6 Nipple reconstructions: (A) Prosthetic nipple—a 57-year-old woman who had previously undergone right immediate LD flap and expandable implant reconstruction. (B) A-C-V flap nipple reconstruction—Pre- and postoperative images of a 49-year-old woman following C-V flap nipple reconstruction undertaken 6 months after her initial implant-only breast mound reconstruction. No adjuvant radiotherapy was needed. (C) Nipple reconstruction using the double-opposing tabs method—a 39-year-old patient was referred to the Cambridge Breast Unit for a second opinion regarding management of local tumor recurrence. She required LD flap chest wall reconstruction and insisted on implant replacement and simultaneous contralateral revision breast augmentation. Nipple reconstruction was achieved with double-opposing tabs, an ideal solution for patients with high oblique scars. Abbreviations: LD, Latissimus dorsi.

The use of AlloDerm RTM (predominantly in United States) has raised the suggestion that it may have a protective effect on adverse capsular contracture (90) although a recent meta-analysis suggests that ADMs may be associated with higher complication rates overall compared with implant-only reconstruction (91). Further long-term outcome reports are awaited.

This option may prove useful in those patients who do not want a complex free flap procedure and want to avoid harvest of the LD muscle. It combines the relative simplicity of an implant-only reconstruction but allows for total coverage of the prosthesis and encourages a more natural-looking

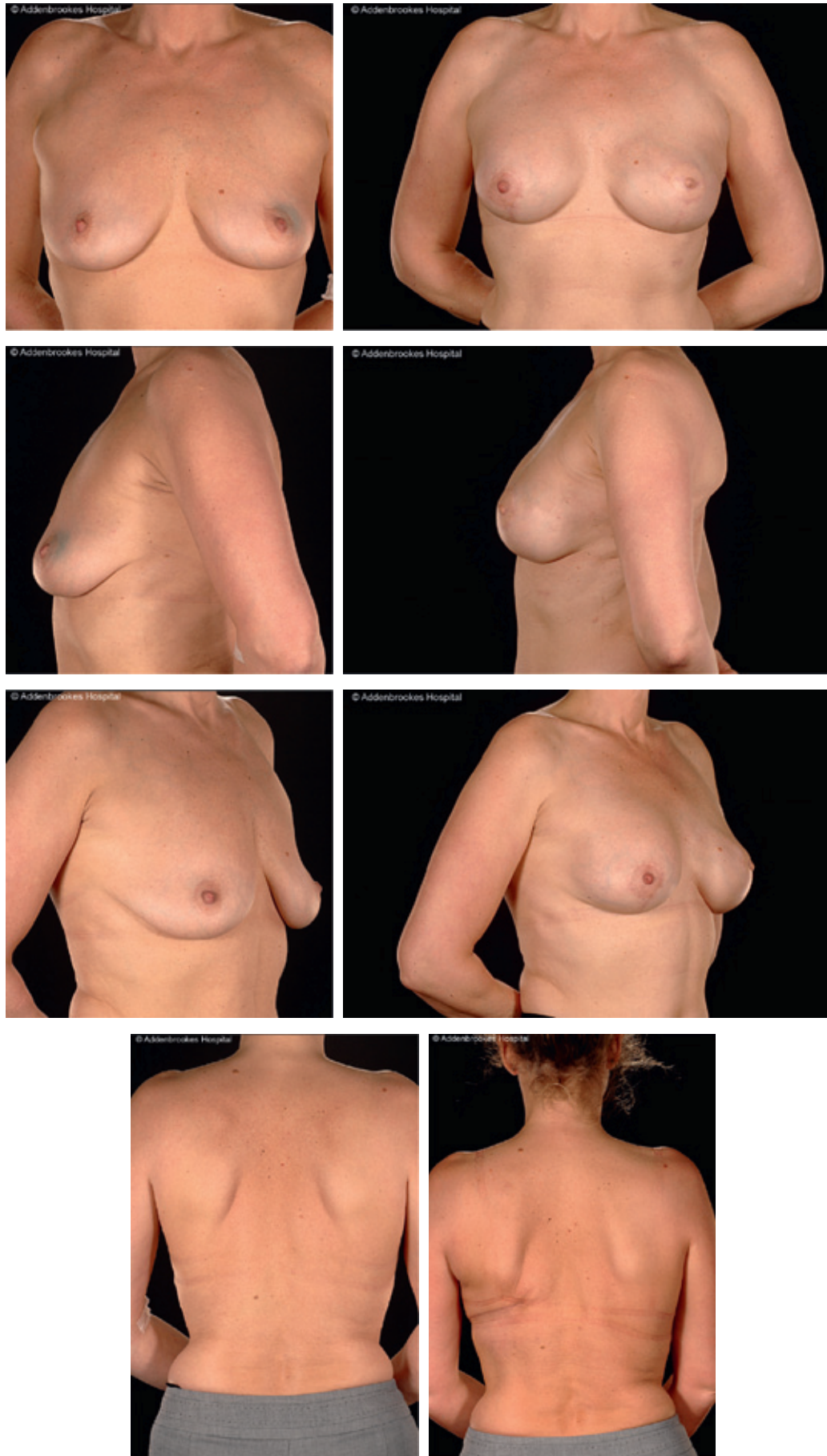implant-based reconstruction. Its place in breast reconstruction has yet to be established.

#### NAC Reconstruction

Often the final stage in breast reconstruction is NAC. As an alternative to a prosthetic nipple (Fig. 51.6A), reconstruction of the NAC can be carried out surgically with autologous grafts or local flaps.

Some surgeons will prefer to undertake this as part of the breast reconstruction procedure; the main advantage of this approach being that it reduces the overall number of surgical





*Figure 51.7* Contralateral balancing surgery: This 50-year-old woman who underwent a left LeJour pattern mastectomy for DCIS and immediate reconstruction with an LD flap and expandable implant and a simultaneous contralateral balancing LeJour augmentation-mastopexy. Note that the postlactational atrophy has been corrected by implant augmentation of the contralateral breast to improve symmetry. The donor site scar is totally hidden when the patient is wearing a bra. *Abbreviations:* DCIS, Ductal carcinoma *in situ*; LD, Latissimus dorsi.

procedures that the patient must undergo. However, NAC reconstruction at the same time as the breast reconstruction should only be carried out if the reconstructive surgeon is confident on the location of the ideal position for the NAC. This may be possible in the case of immediate reconstruction following skin-sparing mastectomy (92).

In the authors' practice, NAC reconstruction is carried out once the primary reconstruction has settled into its final position and the patient has completed any adjuvant treatment. Autologous breast reconstructions tend to sit proud on the chest wall initially and over the subsequent months develop a degree of ptosis (encouraged by massaging) until they rest in what will ultimately be their natural position. It is at this time that NAC reconstruction can be positioned with confidence. This is usually 3 months postoperatively or more than 6 months if the patient has received adjuvant radiotherapy.

Nipple reconstruction can be carried out either by the use of local tissue flaps, such as the CV flap or double-opposing tabs (Figs. 51.6B, C), or by using free grafts (93). The CV flap technique is one of the commonly-used local flap procedures, and involves using a single C-shaped flap, and two V-shaped flaps (or modifications thereof) that are sutured to each other to create the nipple. Grafts can be harvested from the opposite nipple (if it is large enough) or other sites such as the earlobe and labia. Grafts rely on receiving blood supply and nutrition from the recipient bed and hence there is a risk of graft failure with this technique. Local flap techniques, on the other hand, are more reliable in terms of vascularity but are prone to shrinkage with time. Hence these should be made at least twice the predicted size of the eventual nipple to allow for this change.

Often the reconstructed breast skin is insensate and nipple reconstruction can be undertaken without anesthetic. However, if required, a solution containing lidocaine and adrenaline is the local anesthetic of choice.

Areolar reconstruction is often carried out with intradermal tattooing although some surgeons do use full-thickness skin grafts (e.g., from the inner thigh where the skin is often darker to mimic the darker pigmentation of the areola). If an autologous nipple reconstruction has been undertaken, it is sensible to wait for these surgical scars to heal before commencing tattooing (for a period of at least 3 months). Decisions regarding which pigment to use are made in conjunction with the patient, and for unilateral reconstruction, it is based on the color of the contralateral NAC. Intradermal tattooing is generally a safe procedure with a low risk of complications, but patients must be warned of the need for multiple sessions to achieve the final outcome; pigment retention and hence fading of color are highly variable and unpredictable (91). Any history of adverse reactions to tattoo pigment should be ascertained before starting this treatment.

### The Contralateral Breast

Excellent results can be achieved for unilateral breast reconstruction, but as previously mentioned, the ultimate goal is to achieve symmetry with the contralateral breast. In some cases, depending on the size and volume of the contralateral breast, this may not be possible without carrying out a balancing procedure. If a patient is displeased with their breast size and/or shape prior to reconstructive surgery, balancing surgery can be

planned either at the same time as the primary reconstruction or at a later date. Options for symmetrizing surgery include breast augmentation, breast reduction, or uplift (mastopexy) surgery to the contralateral breast.

Careful planning of contralateral surgery may facilitate ipsilateral reconstruction. For example, a patient with large breasts, who might otherwise benefit from reductional surgery, may be able to undergo contralateral reduction and hence require a smaller flap size overall. This would be particularly useful in the case of a patient having autologous flap reconstruction but with a relative paucity of tissue at the desired donor site. A patient with significant breast ptosis may desire an uplift, and skin-reducing mastectomy incisions could be used on the reconstructed side and a mastopexy (with matching skin incisions) carried out contralaterally.

Similarly, in patients with small breasts, the reconstruction can be planned to incorporate contralateral augmentation should the patient desire a larger breast size (Fig. 51.7). There are several advantages of simultaneous contralateral surgery at the time of the primary reconstructive procedure; patients have symmetrization carried out under a single general anesthetic; it avoids waiting for a second procedure and allows for supervised training in such procedures.

### SUMMARY

The techniques available for postmastectomy breast reconstruction vary from comparatively simple implant-only-based reconstruction to complex microsurgical procedures utilizing the patient's own tissues. The decision on choice of procedure is dependent on many factors including the wishes and expectation of patients.

Early reconstructive procedures were limited in esthetic outcomes and often resulted in suboptimal appearance. An important factor that has led to improvement in cosmetic outcome is the evolution of techniques for extirpative surgery. The radical mastectomy of Halsted is rarely performed nowadays due to smaller tumor size at presentation and neoadjuvant therapies. Preservation of local musculature and much of the breast skin envelope has left the reconstructive surgeon with more native tissue at their disposal, and improvements in reconstructive techniques have permitted more esthetic and natural forms of breast reconstruction.

In the absence of radiotherapy, implant-based reconstruction can yield excellent results for smaller-breasted women and is acceptable to many. For the more challenging breast reconstruction involving larger, more ptotic breasts and when radiotherapy is anticipated, autologous flap-based techniques are more appropriate. Moreover, reconstruction using the patient's own tissues remains the current gold standard for breast reconstruction and is associated with superior cosmetic results that are maintained in the longer term.

### ACKNOWLEDGMENTS

Siltex® Contour Profile® Becker 35 and Siltex® Contour Profile® Breast Expanders Style 6100, 6200, 6300—Mentor Corporation, a part of Johnson & Johnson. Natrelle™ 150 and Natrelle™ 133—Allergan, UK. Alloderm® Regenerative Tissue Matrix and Stratattice™ Reconstructive Tissue Matrix—LifeCell Corporation, Branchburg, New Jersey, US.

## REFERENCES

1. Cancer Research UK. <http://info.cancerresearchuk.org/cancerstats/types/breast/incidence>. [accessed on 22 October 2012.]
2. National Mastectomy and Breast Reconstruction Audit 2011, Fourth Annual Report. [Available from: <http://www.ic.nhs.uk/services/national-clinical-audit-support-programme-ncasp/audit-reports/mastectomy-and-breast-reconstruction>] [accessed on 22 October 2012.]
3. Hodgson EL, Malata CM. Implant-based breast reconstruction following mastectomy. *Breast Dis* 2002; 16: 47–63.
4. Goldwyn RM. Vincenz Czerny and the beginnings of breast reconstruction. *Plast Reconstr Surg* 1978; 61: 673–81.
5. Tansini I. Nuovo processo per l'amputazione della mammella per cancro. *La Riforma Medica* 1896; 12: 3. Reprinted in Langenbeck's *Archiv fur Klinische Chirurgie* 1896.
6. Maxwell GP. Iginio Tansini and the origin of the latissimus dorsi musculocutaneous flap. *Plast Reconstr Surg* 1980; 65: 686–92.
7. Olivari N. The latissimus flap. *Br J Plast Surg* 1976; 29: 126–8.
8. Schneider WJ, Hill HL, Brown RG. Latissimus dorsi myocutaneous flap for breast reconstruction. *Br J Plast Surg* 1977; 30: 277–81.
9. Bostwick J 3rd, Vasconez LO, Jurkiewicz MJ. Breast reconstruction after a radical mastectomy. *Plast Reconstr Surg* 1978; 61: 682–93.
10. Cronin TD, Gerow FJ. Augmentation mammoplasty: a new 'natural feel' prosthesis. In: *Proceedings of the 3rd International Congress of Plastic Surgery*. Washington DC. Excerpta Medica Int. Congr. Ser. Number 66. Amsterdam, Excerpta Medica Foundation, 1963. 41–9.
11. Radovan C. Breast reconstruction after mastectomy using the temporary expander. *Plast Reconstr Surg* 1982; 69: 195–208.
12. Orticochea M. Use of the buttock to reconstruct the breast. *Br J Plast Surg* 1973; 26: 304–9.
13. Hartrampf CR, Scheffan M, Black PW. Breast reconstruction with a transverse abdominal island flap. *Plast Reconstr Surg* 1982; 69: 216–25.
14. Holmström H. The free abdominoplasty flap and its use in breast reconstruction. An experimental study and clinical case report. *Scand J Plast Reconstr Surg* 1979; 13: 423–7.
15. Paige KT, Bostwick J 3rd, Bried JT, Jones G. A comparison of morbidity from bilateral, unipedicled and unilateral, unipedicled TRAM flap breast reconstructions. *Plast Reconstr Surg* 1998; 101: 1819–27.
16. Zienowicz RJ, May JW Jr. Hernia prevention and aesthetic contouring of the abdomen following TRAM flap breast reconstruction by the use of polypropylene mesh. *Plast Reconstr Surg* 1995; 96: 1346–50.
17. Boyd JB, Taylor GI, Corlett R. The vascular territories of the superior epigastric and the deep inferior epigastric systems. *Plast Reconstr Surg* 1984; 73: 1–16.
18. El-Mrakby HH, Milner RH. The vascular anatomy of the lower anterior abdominal wall: a microdissection study on the deep inferior epigastric vessels and the perforator branches. *Plast Reconstr Surg* 2002; 109: 539–43.
19. Blondeel N, Vanderstraeten GG, Monstrey SJ, et al. The donor site morbidity of free DIEP flaps and free TRAM flaps for breast reconstruction. *Br J Plast Surg* 1997; 50: 322–30.
20. Koshima I, Soeda S. Inferior epigastric artery skin flaps without rectus abdominis muscle. *Br J Plast Surg* 1989; 42: 645–8.
21. Allen RJ, Treece P. Deep inferior epigastric perforator flap for breast reconstruction. *Ann Plast Surg* 1994; 32: 32–8.
22. Blondeel PN, Boeckx WD. Refinements in free flap breast reconstruction: the free bilateral deep inferior epigastric perforator flap anastomosed to the internal mammary artery. *Br J Plast Surg* 1994; 47: 495–501.
23. Weiler-Mithoff E, Hodgson EL, Malata CM. Perforator flap breast reconstruction. *Breast Dis* 2002; 16: 93–106.
24. Nahabedian MY, Tsangaris T, Momen B. Breast reconstruction with the DIEP flap or the muscle-sparing (MS-2) free TRAM flap: is there a difference? *Plast Reconstr Surg* 2005; 115: 436–44.
25. Elliott LF, Seify H, Bergery P. The 3-hour muscle-sparing free TRAM flap: safe and effective treatment review of 111 consecutive free TRAM flaps in a private practice setting. *Plast Reconstr Surg* 2007; 120: 27–34.
26. Malata CM, McIntosh SA, Purushotham AD. Immediate breast reconstruction after mastectomy for cancer: review. *Br J Surg* 2000; 87: 1455–72.
27. Toth BA, Lappert P. Modified skin incisions for mastectomy: the need for plastic surgical input in preoperative planning. *Plast Reconstr Surg* 1991; 87: 1048–53.
28. Cunliffe GH, Mokbel K. Skin-sparing mastectomy. *Am J Surg* 2004; 188: 78–84.
29. Malata CM, Hodgson EL, Chikwe J, Canal AC, Purushotham AD. An application of the LeJour vertical mammoplasty pattern for skin-sparing mastectomy: a preliminary report. *Ann Plast Surg* 2003; 51: 345–50.
30. Cunliffe GH, Mokbel K. Oncological considerations of skin-sparing mastectomy. *Int Semin Surg Oncol* 2006; 3: 14.
31. Azzawi K, Ismail A, Forouhi P, Earl H, Malata CM. Influence of neoadjuvant chemotherapy on outcomes of immediate breast reconstruction. *Plastic & Reconstructive Surgery* 2010; 126: 1–11. [accessed on 22 October 2012.]
32. American Society of Plastic Surgeons, Report of the 2010 Plastic Surgery Statistics. [Available from: <http://www.plasticsurgery.org/Documents/news-resources/statistics/2010-statistics/Patient-Ages/2010-reconstructive-demographics-breast-surgery-statistics.pdf>] was accessed on 22 October 2012.
33. Spear SL, Spittler CJ. Breast reconstruction with implants and expanders. *Plast Reconstr Surg* 2001; 107: 177–87.
34. Mahdi S, Jones T, Nicklin S, McGeorge DD. Expandable anatomical implants in breast reconstructions: a prospective study. *Br J Plast Surg* 1998; 51: 425–30.
35. Hsieh F, Shah A, Malata CM. Experience with the Mentor Contour Profile Becker-35 expandable implants in reconstructive breast surgery. *J Plast Reconstr Aesthet Surg* 2010; 63: 1124–30.
36. Scuderi N, Alfano C, Campus GV, et al. Multicenter study on breast reconstruction outcome using Becker implants. *Aesthetic Plast Surg* 2011; 35: 66–72.
37. Gui GP, Tan SM, Faliakou EC, et al. Immediate breast reconstruction using bi-dimensional anatomical permanent expander implants: a prospective analysis of outcome and patient satisfaction. *Plast Reconstr Surg* 2003; 111: 125–38.
38. Losken A, Carlson GW, Bostwick J 3rd, et al. Trends in unilateral breast reconstruction and management of the contralateral breast: the Emory experience. *Plast Reconstr Surg* 2002; 110: 89–97.
39. Di Candia M, Lie KH, Forouhi P, Malata CM. Experience with the Wise mammoplasty skin resection pattern in skin-sparing mastectomy and immediate breast reconstruction for large breast volumes. *Int J Surg* 2011; 9: 41–5.
40. Mustoe TA, Bartell TH, Garner WL. Physical, biomechanical, histologic, and biochemical effects of rapid versus conventional tissue expansion. *Plast Reconstr Surg* 1989; 83: 687–91.
41. Malata CM, Williams NW, Sharpe DT. Tissue expansion: an overview. *J Wound Care* 1995; 4: 37–44.
42. Spear SL, Baker JL Jr. Classification of capsular contracture after prosthetic breast reconstruction. *Plast Reconstr Surg* 1995; 96: 1119–23.
43. Malata CM, Feldberg L, Coleman DJ, Foo IT, Sharpe DT. Textured or smooth implants for breast augmentation? Three year follow-up of a prospective randomised controlled trial. *Br J Plast Surg* 1997; 50: 99–105.
44. Hakelius L, Ohlén L. Tendency to capsular contracture around smooth and textured gel-filled silicone mammary implants: a five-year follow-up. *Plast Reconstr Surg* 1997; 100: 1566–9.
45. Whitfield GA, Horan G, Irwin MS, et al. Incidence of severe capsular contracture following implant-based immediate breast reconstruction with or without postoperative chest wall radiotherapy using 40 Gray in 15 fractions. *Radiother Oncol* 2009; 90: 141–7.
46. Dickson MG, Sharpe DT. The complications of tissue expansion in breast reconstruction. A review of 75 cases. *Br J Plast Surg* 1987; 40: 629–35.
47. Nahabedian MY, Tsangaris T, Momen B, Manson PN. Infectious complications following breast reconstruction with expanders and implants. *Plast Reconstr Surg* 2003; 112: 467–76.
48. Martano A, Malata CM. Accidental latissimus dorsi flap pedicle avulsion during immediate breast reconstruction: salvage by conversion to free flap. *J Plast Reconstr Aesthet Surg* 2012; 65: 1107–10.
49. Hammond DC. Latissimus dorsi flap breast reconstruction. *Plast Reconstr Surg* 2009; 124: 1055–63.
50. Gerber B, Krause A, Reimer T, Müller H, Friese K. Breast reconstruction with latissimus dorsi flap: improved aesthetic results after transection of its humeral insertion. *Plast Reconstr Surg* 1999; 103: 1876–81.
51. Germann G, Steinau HU. Breast reconstruction with the extended latissimus dorsi flap. *Plast Reconstr Surg* 1996; 97: 519–26.
52. Delay E, Gounot N, Bouillot A, Zlatoff P, Rivoire M. Autologous latissimus breast reconstruction: a 3-year clinical experience with 100 patients. *Plast Reconstr Surg* 1998; 102: 1461–78.
53. Sinna R, Delay E, Garson S, Delaporte T, Toussoun G. Breast fat grafting (lipomodelling) after extended latissimus dorsi flap breast reconstruction:



- A preliminary report of 200 consecutive cases. *J Plast Reconstr Aesthet Surg* 2010; 63: 1769–77.
54. Titley OG, Spyrou GE, Fatah MF. Preventing seroma in the latissimus dorsi flap donor site. *Br J Plast Surg* 1997; 50: 106–8.
  55. Forthomme B, Heymans O, Jacquemin D, et al. Shoulder function after latissimus dorsi transfer in breast reconstruction. *Clin Physiol Funct Imaging* 2010; 30: 406–12.
  56. Spear SL, Hess CL. A review of the biomechanical and functional changes in the shoulder following transfer of the latissimus dorsi muscles. *Plast Reconstr Surg* 2005; 115: 2070–3.
  57. Losken A, Nicholas CS, Pinell XA, Carlson GW. Outcomes evaluation following bilateral breast reconstruction using latissimus dorsi myocutaneous flaps. *Ann Plast Surg* 2010; 65: 17–22.
  58. Atisha D, Alderman AK. A systematic review of abdominal wall function following abdominal flaps for postmastectomy breast reconstruction. *Ann Plast Surg* 2009; 63: 222–30.
  59. Kroll SS, Gherardini G, Martin JE, et al. Fat necrosis in free and pedicled TRAM flaps. *Plast Reconstr Surg* 1998; 102: 1502–7.
  60. Garvey PB, Buchel EW, Pockaj BA, et al. DIEP and pedicled TRAM flaps: a comparison of outcomes. *Plast Reconstr Surg* 2006; 117: 1711–19.
  61. Moon HK, Taylor GI. The vascular anatomy of rectus abdominis musculocutaneous flaps based on the deep superior epigastric system. *Plast Reconstr Surg* 1988; 82: 815–32.
  62. Holm C, Mayr M, Höfner E, Ninkovic M. Perfusion zones of the DIEP flap revisited: a clinical study. *Plast Reconstr Surg* 2006; 117: 37–43.
  63. Hsieh F, Kumiponjera D, Malata CM. An algorithmic approach to abdominal flap breast reconstruction in patients with pre-existing scars: results from a single surgeon's experience. *J Plast Reconstr Aesthet Surg* 2009; 62: 1650–60.
  64. Di Candia M, Al-Asfoor A, Mickute Z, Kumiponjera D, Hsieh F, Malata CM. Previous multiple abdominal surgery: A valid contraindication to abdominal free flap breast reconstruction? *E-Plasty* 2012; 12: e31: 286–303. Epub July 23. PMID: 22848775.
  65. Mathes DW, Neligan PC. Preoperative imaging techniques for perforator selection in abdomen-based microsurgical breast reconstruction. *Clin Plast Surg* 2010; 37: 581–91.
  66. Grotting JC. The free abdominoplasty flap for immediate breast reconstruction. *Ann Plast Surg* 1991; 27: 351.
  67. Arnez ZM, Khan U, Pogorelec D, Planinsek F. Breast reconstruction using the free superficial inferior epigastric artery (SIEA) flap. *Br J Plast Surg* 1999; 52: 276–9.
  68. Holm C, Mayr M, Höfner E, Ninkovic M. The versatility of the SIEA flap: a clinical assessment of the vascular territory of the superficial epigastric inferior artery. *J Plast Reconstr Aesthet Surg* 2007; 60: 946–51.
  69. Allen RJ, Heitland AS. Superficial inferior epigastric artery flap for breast reconstruction. *Semin Plast Surg* 2002; 16: 35.
  70. Gusenoff JA, Coon D, De La Cruz C, Rubin JP. Superficial inferior epigastric vessels in the massive weight loss population: implications for breast reconstruction. *Plast Reconstr Surg* 2008; 122: 1621–6.
  71. Blondeel PN, Arnstein M, Verstraete K, et al. Venous congestion and blood flow in free transverse rectus abdominis myocutaneous and deep inferior epigastric perforator flaps. *Plast Reconstr Surg* 2000; 106: 1295–9.
  72. Shaw WW. Breast reconstruction by superior gluteal microvascular free flaps without silicone implants. *Plast Reconstr Surg* 1983; 72: 490–501.
  73. Codner MA, Nahai F. The gluteal free flap breast reconstruction. Making it work. *Clin Plast Surg* 1994; 21: 289–96.
  74. Allen RJ, Tucker T Jr. Superior gluteal artery perforator free flap for breast reconstruction. *Plast Reconstr Surg* 1995; 95: 1207–12.
  75. Allen RJ, Levine JL, Granzow JW. The in-the-crease inferior gluteal artery perforator flap for breast reconstruction. *Plast Reconstr Surg* 2006; 118: 333–9.
  76. Arnez ZM, Pogorelec D, Planinsek F, et al. Breast reconstruction by the free transverse gracilis (TMG) flap. *Br J Plast Surg* 2004; 57: 20–6.
  77. Schoeller T, Wechselberger G. Breast reconstruction by the free transverse gracilis (TMG) flap. *Br J Plast Surg* 2004; 57: 481–2.
  78. Fattah A, Figus A, Mathur B, Ramakrishnan VV. The transverse myocutaneous gracilis flap: technical refinements. *J Plast Reconstr Aesthet Surg* 2010; 63: 305–13.
  79. Ninković M, Anderl H, Hefel L, Schwabegger A, Wechselberger G. Internal mammary vessels: a reliable recipient system for free flaps in breast reconstruction. *Br J Plast Surg* 1995; 48: 533–9.
  80. Majumder S, Batchelor AG. Internal mammary vessels as recipients for free TRAM breast reconstruction: aesthetic and functional considerations. *Br J Plast Surg* 1999; 52: 286–9.
  81. Parrett BM, Caterson SA, Tobias AM, Lee BT. The rib-sparing technique for internal mammary vessel exposure in microsurgical breast reconstruction. *Ann Plast Surg* 2008; 60: 241–3.
  82. Malata CM, Moses M, Mickute Z, Di Candia M. Tips for successful microvascular abdominal flap breast reconstruction utilizing the “total rib preservation” technique for internal mammary vessel exposure. *Ann Plast Surg* 2011; 66: 36–42.
  83. Moran SL, Nava G, Behnam AB, Serletti JM. An outcome analysis comparing the thoracodorsal and internal mammary vessels as recipient sites for microvascular breast reconstruction: a prospective study of 100 patients. *Plast Reconstr Surg* 2003; 111: 1876–82.
  84. Banwell M, Trotter D, Ramakrishnan V. The thoracodorsal artery and vein as recipient vessels for microsurgical breast reconstruction. *Ann Plast Surg* 2012; 68: 542–3.
  85. Sbitany H, Sandeen SN, Amalfi AN, Davenport MS, Langstein HN. Acellular dermis-assisted prosthetic breast reconstruction versus complete submuscular coverage: a head-to-head comparison of outcomes. *Plast Reconstr Surg* 2009; 124: 1735–40.
  86. Spear SL, Parikh PM, Reisin E, Menon NG. Acellular dermis-assisted breast reconstruction. *Aesthetic Plast Surg* 2008; 32: 418–25.
  87. Bain C, Lancaster K, Mohanna P, Farhadi J, Ho-Asjoe M. Can Acellular Dermal Matrix (ADM) replace the latissimus dorsi flap in breast reconstruction? Presented at BAPRAS Winter Scientific Meeting. Royal College of Surgeons of England, London, UK, 01 December 2010.
  88. Connor J, McQuillan D, Sandor M, et al. Retention of structural and biochemical integrity in a biological mesh supports tissue remodeling in a primate abdominal wall model. *Regen Med* 2009; 4: 185–95.
  89. Katerinaki E, Zanetto U, Sterne GD. Histological appearance of Strattice tissue matrix used in breast reconstruction. *J Plast Reconstr Aesthet Surg* 2010; 63: e840–1.
  90. Salzberg CA, Ashikari AY, Koch RM, Chabner-Thompson E. An 8-year experience of direct-to-implant immediate breast reconstruction using human acellular dermal matrix (AlloDerm). *Plast Reconstr Surg* 2011; 127: 514–12.
  91. Kim JY, Davila AA, Persing S, et al. A meta-analysis of human acellular dermis and submuscular tissue expander breast reconstruction. *Plast Reconstr Surg* 2012; 129: 28–41.
  92. Delay E, Mojallal A, Vasseur C, Delaporte T. Immediate nipple reconstruction during immediate autologous latissimus breast reconstruction. *Plast Reconstr Surg* 2006; 118: 1303–12.
  93. Tyrone JW, Losken A, Hester TR. Nipple areola reconstruction. *Breast Dis* 2002; 16: 117–22.

# AUTHOR INFORMATION SHEET

## 51 The principles of breast reconstructive surgery

**Animesh JK Patel**

Department of Plastic Surgery  
Addenbrooke's Hospital  
Cambridge University Hospitals NHS Foundation Trust  
Cambridge, UK

**Rosanna C Ching**

Department of Plastic Surgery  
Addenbrooke's Hospital  
Cambridge University Hospitals NHS Foundation Trust  
Cambridge, UK

**John R Benson**

Cambridge Breast Unit  
Addenbrooke's Hospital  
Cambridge University Hospitals NHS Foundation Trust  
Cambridge, UK

**Charles M Malata**

Cambridge Breast Unit & Department of Plastic Surgery  
Addenbrooke's Hospital  
Cambridge University Hospitals NHS Foundation Trust  
Cambridge, UK  
E-mail: [cmalata@hotmail.com](mailto:cmalata@hotmail.com)