



ELSEVIER



CORRESPONDENCE AND COMMUNICATION

Innovative surgical treatment of persistent unilesional breast mycosis fungoides by mastopexy

Dear Sir,

Mycosis Fungoides (MF) is the most common cutaneous T cell lymphoma.¹ It presents with patches which can progress to tumours and finally leukaemia. MF is staged according to a tumour-node-metastasis-blood (TNMB) system and prognosis decreases significantly with increasing stage and its leukaemic variant Sézary's syndrome has a very poor prognosis.¹ Unilesional MF has a distinct clinical presentation but is indistinguishable from other forms histologically.² It tends to have a favourable prognosis without systemic spread however it can spread cutaneously.²

A 28-year-old woman with a 9 year history of MF of the left breast was referred for plastic surgery by dermatology for a persistent papillomatous stage 1A MF plaque following previous radiotherapy. She had been under their care for the preceding four years. At the time of referral the plaque was extensive and involved the nipple areolar complex and adjacent skin (Figure 1, left). It had many crevices which were a source of recurrent infection and was frequently malodorous. There were no other areas of skin involvement on her body however the lesion's appearance and its symptoms had become a major source of distress to the patient. She underwent excision of the periareolar MF using the LeJour mammoplasty skin resection pattern and a simultaneous contralateral balancing LeJour mastopexy. The operation was uneventful and there were no post-operative complications. Histology confirmed the presence of MF with clear resection margins and seven months later she remains disease-free (Figure 1, right).

MF has no widely accepted treatment standards though guidelines were published in 2007.¹ These include working up from topical treatment for early stage disease to systemic therapy for advanced disease.¹ These systemic therapies can carry significant side effects and surgical treatment is not emphasised. Since unilesional MF is both rare and at a cellular level indistinguishable from classic

MF² specific treatment plans are not available. There were no previous reports of surgical excision of MF presenting in the breast but successful excision has been reported in the trunk² and in cases where excision was incomplete, radiotherapy was effective in inducing prolonged absence of symptoms if not cure.⁵ Radiotherapy is known to be particularly successful in achieving long term remission with reports of 100% response rates though relapses do occur. In one case the recurring patches were distant from the original site,³ suggesting a continued metastatic potential despite the typically indolent course of unilesional MF. Other forms of therapy reported include nitrogen mustards and steroids.^{2,3} The authors could find no reports of unilesional MF unresponsive to sustained conservative treatment, this is in contrast to our patient who had undergone years of therapy with little effect. In addition her MF remained strictly localised throughout its long time course, in contrast to classic MF which will spread with time suggesting this was indeed a specific variant of MF rather than merely the early presentation of a slowly growing classic form. This has been hypothesized before.⁴

Given the considerable side effects of the aforementioned topical treatments and radiation therapy, with some presentations of unilesional MF surgery may provide the least harmful solution to the patient. In addition, the cases of recurrence reported after conservative therapies and the reported capacity of unilesional MF to spread cutaneously forming multiple lesions² suggests that excision may be the most certain method of removing the risk of metastases.

In our patient the LeJour mastopexy technique provided a surgical solution as it entailed effective resection of the involved skin. The patient lost weight so loose skin combined with the periareolar distribution of the MF rendered it amenable to excision while improving the patient's aesthetic appearance. This course of action is only appropriate in patients with large or ptotic breasts. Our patient fell into this category and welcomed the potential improvement in the shape of her ptotic breasts despite committing to surgery on the opposite normal breast. In addition to aesthetic enhancement the skin resection provided an opportunity for histological examination to exclude the presence of malignant cells. This is important because the skin resection involved only narrow deep

<http://dx.doi.org/10.1016/j.bjps.2014.08.007>

1748-6815/© 2014 British Association of Plastic, Reconstructive and Aesthetic Surgeons. Published by Elsevier Ltd. All rights reserved.

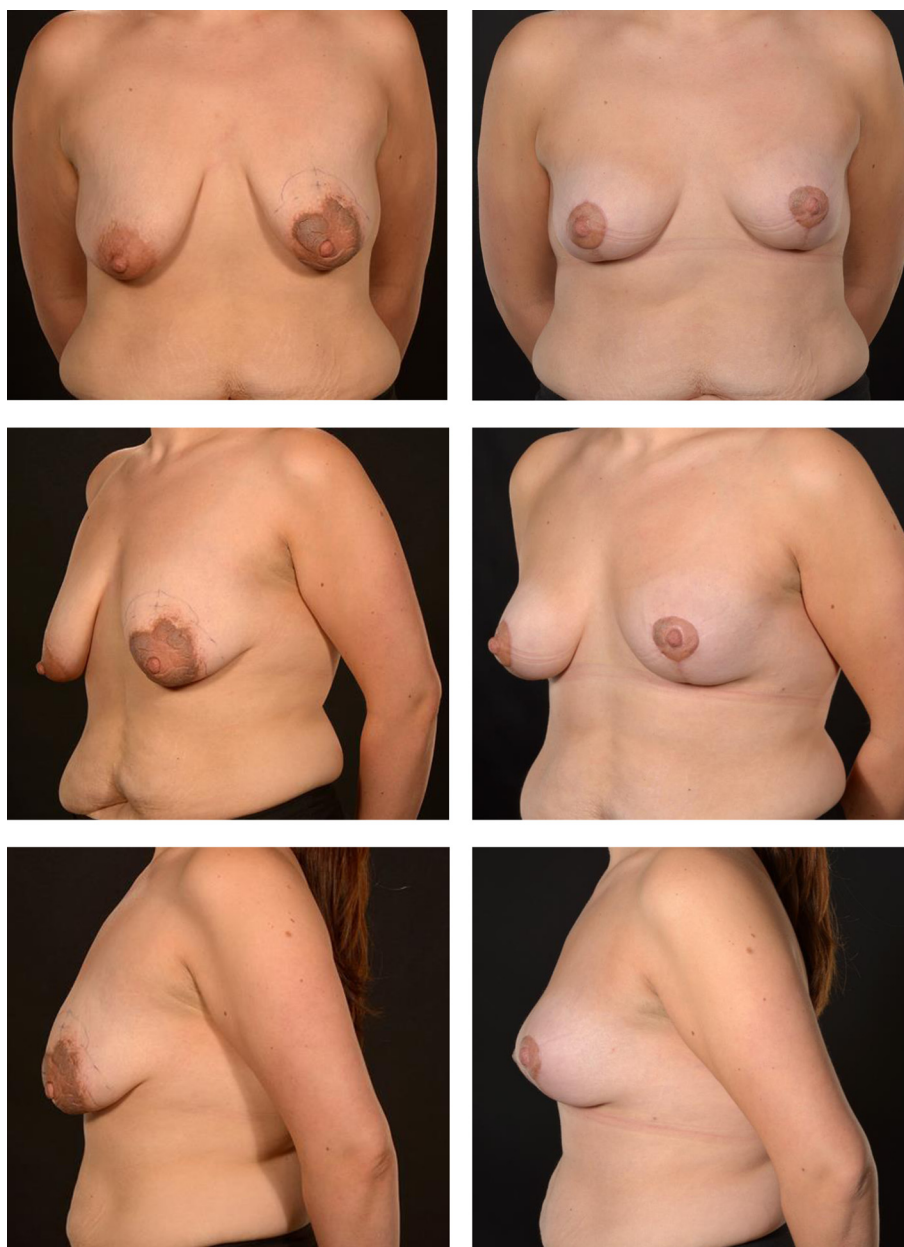


Figure 1 Pre and post-operative photographs of a 28 year old patient showing the favourable distribution of her mycosis fungoides and its complete resection with incidental improvement in the cosmetic appearance of the nipple areolar complex and breast shape.

margins in order not to devascularize the nipple areolar complex during the deep periareolar resection.

The case herein reported illustrates an effective solution for unilesional MF of the breast highly resistant to conservative therapy. There was no morbidity but a distinct improvement in its cosmetic appearance. Surgical excision represents a feasible treatment option in certain presentations of MF involving the central breast mound which may prove useful in recalcitrant, localised MF.

Conflict of interest

None.

Funding sources

None.

References

1. Horwitz SM, Olsen EA, Duvic M, et al. Review of the treatment of mycosis fungoides and sezary syndrome: a stage-based approach. *J Natl Compr Canc Netw* 2008;6(4): 436–42.
2. Hodak E, Phenig E, Amichai B, et al. Unilesional mycosis fungoides: a study of seven cases. *Dermatology* 2000;201(4): 300–6.

3. Micaily B, Miyamoto C, Kantor G, et al. Radiotherapy for unilesional mycosis fungoides. *Int J Radiat Oncol Biol Phys* 1998 Sep 1;**42**(2):361–4.
4. Verret JL, Rousselet MC, Peria P. Unilesional plaque-type mycosis fungoides: 3 cases. *Ann Dermatol Venereol* 1997; **124**(8):527–30.
5. Ally MS, Pawade J, Tanaka M, et al. Solitary mycosis fungoides: a distinct clinicopathologic entity with a good prognosis: a series of 15 cases and literature review. *J Am Acad Dermatol* 2012 Oct;**67**(4):736–44.

J.E. Brooker
School of Clinical Medicine,
University of Cambridge,
United Kingdom

C.M. Malata
Department of Plastic & Reconstructive Surgery,
Cambridge University Hospitals NHS Foundation Trust,
United Kingdom

Cambridge Breast Unit, United Kingdom
Postgraduate Medical Institute, Anglia Ruskin University
(Chelmsford & Cambridge), United Kingdom

E-mail addresses: cmalata@hotmail.com,
charles.malata@addenbrookes.nhs.uk

18 May 2014